

Get Full Access and More at

ExpertConsult.com

Edited by

June K Robinson

C William Hanke

Daniel M Siegel

Alina Fratila



Third Edition

# Surgery of the Skin


Procedural Dermatology

Video Editors

Ashish C Bhatia

Thomas E Rohrer

ELSEVIER  
SAUNDERS



Third Edition

# Surgery of the Skin

Procedural Dermatology

For Elsevier:

Content Strategist: Russell Gabbedy

Content Development Specialist: Sam Crowe/Poppy Garraway

Project Manager: Julie Taylor

Design: Miles Hitchen

Illustrator: Antbits Ltd

Marketing Manager: David Dunlap



Third Edition

# Surgery of the Skin

Procedural Dermatology

## Editors

### June K Robinson MD

Professor of Clinical Dermatology  
Department of Dermatology  
Northwestern University, Feinberg School of Medicine  
Chicago, IL, USA

### C William Hanke MD MPH FACP

Visiting Professor of Dermatology  
University of Iowa, Carver College of Medicine  
Iowa City, Iowa  
Clinical Professor of Otolaryngology, Head and Neck Surgery  
Indiana University School of Medicine  
Indianapolis, IN, USA

### Daniel M Siegel MD MS

Clinical Professor of Dermatology  
Department of Dermatology  
SUNY Downstate Medical Center  
College of Medicine  
Brooklyn, NY, USA  
Senior Surgeon  
Long Island Skin Cancer and Dermatologic Surgery, a division of  
ProHEALTH Care Associates  
Smithtown, NY, USA

### Alina Fratila MD

Medical Director  
Jungbrunnen-Klinik Dr. Fratila GmbH  
Bonn, Germany  
Associate Professor  
Victor Babes University of Medicine and Pharmacy  
Timisoara, Romania


## Video Editors

### Ashish C Bhatia MD FAAD

Associate Professor of Clinical Dermatology  
Department of Dermatology  
Northwestern University, Feinberg School of Medicine  
Chicago, IL, USA  
Medical Director for Dermatologic Research, DuPage Medical Group  
Chairman, Department of Dermatology, DuPage Medical Group  
Co-Director of Dermatologic, Laser & Cosmetic Surgery  
The Dermatology Institute  
Naperville, IL, USA

### Thomas E Rohrer MD

Associate Clinical Professor of Dermatology  
Brown University School of Medicine  
Providence, RI, USA  
Private Practice  
SkinCare Physicians  
Chestnut Hill, MA, USA



**ExpertConsult.com**  Video On-Line

For additional online content visit [expertconsult](http://expertconsult)

London, New York, Oxford, Philadelphia, St Louis, Sydney, Toronto 2015

SAUNDERS an imprint of Elsevier Inc.

© 2015, Elsevier Inc. All rights reserved.

First edition 2005

Second edition 2010

Third edition 2015. Elsevier Inc. All rights reserved.

No part of this publication may be reproduced or transmitted in any form or by any means, electronic or mechanical, including photocopying, recording, or any information storage and retrieval system, without permission in writing from the publisher. Details on how to seek permission, further information about the Publisher's permissions policies and our arrangements with organizations such as the Copyright Clearance Center and the Copyright Licensing Agency, can be found at our website: [www.elsevier.com/permissions](http://www.elsevier.com/permissions).

This book and the individual contributions contained in it are protected under copyright by the Publisher (other than as may be noted herein).

Naomi Lawrence and Shari Nemeth have retained copyright of their figures and tables in Chapter 28, Liposuction.

ISBN: 978-0-323-26027-5

eISBN: 978-0-323-26028-2

#### Notices

Knowledge and best practice in this field are constantly changing. As new research and experience broaden our understanding, changes in research methods, professional practices, or medical treatment may become necessary.

Practitioners and researchers must always rely on their own experience and knowledge in evaluating and using any information, methods, compounds, or experiments described herein. In using such information or methods they should be mindful of their own safety and the safety of others, including parties for whom they have a professional responsibility.

With respect to any drug or pharmaceutical products identified, readers are advised to check the most current information provided (i) on procedures featured or (ii) by the manufacturer of each product to be administered, to verify the recommended dose or formula, the method and duration of administration, and contraindications. It is the responsibility of practitioners, relying on their own experience and knowledge of their patients, to make diagnoses, to determine dosages and the best treatment for each individual patient, and to take all appropriate safety precautions.

To the fullest extent of the law, neither the Publisher nor the authors, contributors, or editors, assume any liability for any injury and/or damage to persons or property as a matter of products liability, negligence or otherwise, or from any use or operation of any methods, products, instructions, or ideas contained in the material herein.



The  
publisher's  
policy is to use  
**paper manufactured  
from sustainable forests**

Printed in China

Last digit is the print number: 9 8 7 6 5 4 3 2 1

# Contents

<i>Video Table of Contents</i>	<i>viii</i>
<i>Preface</i>	<i>xii</i>
<i>List of Contributors</i>	<i>xiii</i>
<i>Dedication</i>	<i>xvii</i>
<i>Acknowledgments</i>	<i>xviii</i>

## PART 1 : Basic Surgical Concepts

---

1. Anatomy for Procedural Dermatology	1
<i>June K Robinson</i>	
2. Aseptic Technique	28
<i>Christie R Travelute and Todd V Cartee</i>	
3. Anesthesia and Analgesia	43
<i>Teresa T Soriano, Andrew Breithaupt, and Cameron Chesnut</i>	
4. Instruments and Materials	64
<i>William Lear</i>	
5. Patient Evaluation, Informed Consent, Preoperative Assessment, and Care	74
<i>Mara C Weinstein and Allison T Vidimos</i>	
6. Antibiotics	85
<i>Kavita Mariwalla</i>	
7. Wound Healing	95
<i>Sonia Lamel, Jie Li, and Robert S Kirsner</i>	
8. Wound Healing and Its Impact on Dressings and Postoperative Care	114
<i>Yakir Levin, Katherine L Brown, and Tania J Phillips</i>	

## PART 2 : Essential Surgical Skills

---

9. Electrosurgery	134
<i>Diana Bolotin and Murad Alam</i>	
10. Cryosurgery	150
<i>Paola Pasquali</i>	
11. Skin Biopsy Techniques	165
<i>Andrew G Affleck and Graham Colver</i>	
12. Incision, Draining, and Exteriorization Techniques	177
<i>Masato Yasuta</i>	
13. Suturing Technique and Other Closure Materials	193
<i>Divya Srivastava and R Stan Taylor</i>	
14. Complex Layered Facial Closures	214
<i>Edgar F Fincher, Hayes B Gladstone, and Ronald L Moy</i>	
15. Hemostasis	227
<i>Pedro Redondo</i>	

16. Ellipse, Ellipse Variations, and Dog-ear Repairs	239
<i>Allison Hanlon, Samuel E Book, and David J Leffell</i>	
17. Random Pattern Cutaneous Flaps	252
<i>Jonathan L Cook, Glenn D Goldman, and Todd E Holmes</i>	
18. Axial Pattern Flaps	286
<i>Christopher J Miller, Tri Nguyen, and Joseph F Sobanko</i>	
19. Skin Grafting	306
<i>Alvaro E Acosta, Sumaira Z Aasi, Robert J MacNeal, Michael J Messingham, and Christopher J Arpey</i>	
20. Acne Scar Revision	324
<i>Greg J Goodman</i>	
21. Revision of Surgical Scars	336
<i>Justin J Leitenberger, Scott N Isenhath, Neil A Swanson, and Ken K Lee</i>	

### PART 3 : Aesthetic Surgical Procedures

---

22. Psychosocial Issues and the Cosmetic Surgery Patient	346
<i>Dee Anna Glaser</i>	
23. Evaluation and Management of the Aging Face	357
<i>Lisa M Donofrio</i>	
24. Soft-tissue Augmentation	367
<i>C William Hanke, Emily P Tierney, Nicholas B Countryman, Berthold Rzany, and Gerhard Sattler</i>	
25. Chemical Peels	393
<i>Marina Landau and Sahar F Ghannam</i>	
26. Implants	409
<i>J Michael Carney</i>	
27. Botulinum Toxins	427
<i>Doris Hexsel and Camile L Hexsel</i>	
28. Liposuction	441
<i>C William Hanke, Naomi Lawrence, Shari Nemeth Ochoa, Nicholas B Countryman, and Gerhard Sattler</i>	
29. Autologous Fat Transfer: Evolving Concepts and Techniques	464
<i>Kimberly J Butterwick</i>	
30. Follicular Unit Hair Transplantation	478
<i>Robert M Bernstein</i>	
31. Laser Hair Removal	509
<i>William G Stebbins, Sandy S Tsao, George J Hruza, and C William Hanke</i>	
32. Laser Treatment of Tattoos and Pigmented Lesions	524
<i>Rachel N Pritzker, Vivek Iyengar, Thomas E Rohrer, and Kenneth A Arndt</i>	
33. Photodynamic Therapy	536
<i>Anne Goldsberry, C William Hanke, Carmen Salavastu, and Daniel Siegel</i>	
34. Laser-based Treatment of the Aging Face for Skin Resurfacing: Ablative and Non-ablative Lasers	549
<i>Omar A Ibrahim, Nazanin Saedi, and Suzanne L Kilmer</i>	
35. Laser and Light Treatment of Acquired and Congenital Vascular Lesions	561
<i>Johnny Chun Yin Chan and Henry Hin Lee Chan</i>	

36. Sclerotherapy of Varicose Veins	581
<i>Eberhard Rabe, Franz X Breu, and Felizitas Pannier</i>	
37. Endovenous Thermal Ablation Techniques with Ambulatory Phlebectomy for Varicose Veins	588
<i>Sanja Schuller-Petrović, Felizitas Pannier, and Miloš D Pavlović</i>	
38. Lamellar High-SMAS Minimum Incision Face Lift	599
<i>Robert C Langdon</i>	
39. Vertical Vector Face Lift with Local Anesthesia	613
<i>Rafael A Schulze, Brian Somoano, and Greg S Morganroth</i>	
40. Blepharoplasty and Brow-lift	625
<i>Alina Fratila and Young Kyoon Kim</i>	
41. Rejuvenation of the Neck Using Liposuction and Other Techniques	649
<i>William G Stebbins, Michael S Kaminer, and C William Hanke</i>	
42. Rejuvenation of the External Female Genitalia	666
<i>Doris Hexsel, Sebastian Pop, and Antonio Rusciani</i>	

## PART 4 : Special Procedures

43. Keloid Management	673
<i>Brian Berman, Sadegh Amini, and Hilary Baldwin</i>	
44. Vitiligo Surgery	688
<i>Niti Khunger, Koushik Lahiri, and Venkataram Mysore</i>	
45. Mohs Micrographic Surgery and Cutaneous Oncology	702
<i>Hubert T Greenway, Kurt L Maggio, Robert Lane, Theresa Cao, and Amor Khachemoune</i>	
46. Leg Ulcer Management	729
<i>Ysabel Bello, Carlos A Charles, Anna F Falabella, and Adolfo C Fernández-Obregón</i>	
47. Nail Surgery	755
<i>Eckart Haneke</i>	
48. Repair of the Split Earlobe, Ear Piercing, and Earlobe Reduction	781
<i>Sirunya Silapunt and Leonard H Goldberg</i>	
49. Hidradenitis Suppurativa	793
<i>Virginia J Reeder, David Ozog, and Iltefat Hamzavi</i>	
50. Assessment and Treatment of Photoaging-related Mottled Pigmentation	804
<i>Se Young Na and Kyoung Chan Park</i>	

## PART 5 : Office-Based Surgery: Physical and Regulatory

51. Design of the Surgical Suite, Including Large Equipment, and Monitoring Devices	811
<i>Ross M Levy and C William Hanke</i>	
52. Dermatology Office Accreditation	820
<i>Ross M Levy, Emily Tierney, and C William Hanke</i>	
Index	837



# ▶ Video Table of Contents

## PART I: Basic Surgical Concepts

### 1. Anatomy for Procedural Dermatology

#### 1.1 Facial dissection

June K Robinson

### 2. Aseptic Technique

#### 2.1 Prepping the patient

Christie R Travelute and Todd V Cartee

#### 2.2 Set-up of sterile tray

Christie R Travelute and Todd V Cartee

### 3. Anesthesia and Analgesia

#### 3.1 Injection basics

Teresa T Soriano, Andrew Breithaupt, and Cameron Chesnut

#### 3.2 Tumescence anesthesia of neck and jowls

Michael S Kaminer

#### 3.3 Supraorbital nerve block

Teresa T Soriano, Andrew Breithaupt, and Cameron Chesnut

#### 3.4 Infraorbital nerve block

Teresa T Soriano, Andrew Breithaupt, and Cameron Chesnut

#### 3.5 Intraoral blocks: an additional perspective

Ashish C Bhatia and Thomas E Rohrer

#### 3.6 Digital nerve block

Teresa T Soriano, Andrew Breithaupt, and Cameron Chesnut

#### 3.7 Mental nerve block

Teresa T Soriano, Andrew Breithaupt, and Cameron Chesnut

#### 3.8 Intraoral injection

Teresa T Soriano, Andrew Breithaupt, and Cameron Chesnut

#### 3.9 Wrist blocks: cadaveric anatomy

Dominic Harmon

From *Peripheral Nerve Blocks & Peri-Operative Pain Relief*, edited by Dominic Harmon. Copyright Elsevier 2010.

#### 3.10 Wrist blocks: surface anatomy

Dominic Harmon

From *Peripheral Nerve Blocks & Peri-Operative Pain Relief*, edited by Dominic Harmon. Copyright Elsevier 2010.

#### 3.11 Wrist blocks: technique

Dominic Harmon

From *Peripheral Nerve Blocks & Peri-Operative Pain Relief*, edited by Dominic Harmon. Copyright Elsevier 2010.

#### 3.12 Median nerve block

Teresa T Soriano, Andrew Breithaupt, and Cameron Chesnut

#### 3.13 Posterior tibial nerve block

Teresa T Soriano, Andrew Breithaupt, and Cameron Chesnut

#### 3.14 Ankle block: surface anatomy

Dominic Harmon

From *Peripheral Nerve Blocks & Peri-Operative Pain Relief*, edited by Dominic Harmon. Copyright Elsevier 2010.

#### 3.15 Ankle block: cadaveric anatomy

Dominic Harmon

From *Peripheral Nerve Blocks & Peri-Operative Pain Relief*, edited by Dominic Harmon. Copyright Elsevier 2010.

#### 3.16 Ankle block: technique 1

Dominic Harmon

From *Peripheral Nerve Blocks & Peri-Operative Pain Relief*, edited by Dominic Harmon. Copyright Elsevier 2010.

#### 3.17 Ankle block: technique 2

Dominic Harmon

From *Peripheral Nerve Blocks & Peri-Operative Pain Relief*, edited by Dominic Harmon. Copyright Elsevier 2010.

#### 3.18 Sural nerve block

Teresa T Soriano, Andrew Breithaupt, and Cameron Chesnut

#### 3.19 Ulnar nerve block

Teresa T Soriano, Andrew Breithaupt, and Cameron Chesnut

#### 3.20 Saphenous nerve block

Teresa T Soriano, Andrew Breithaupt, and Cameron Chesnut

#### 3.21 Superficial peroneal nerve block

Teresa T Soriano, Andrew Breithaupt, and Cameron Chesnut

### 4. Instruments and Materials

#### 4.1 Ancillary instruments

William Lear

#### 4.2 Scalpels and blades

William Lear

#### 4.3 Scissors

William Lear

#### 4.4 Needle drivers

William Lear

#### 4.5 Reading suture packages

William Lear

#### 4.6 Staples

William Lear

### 7. Wound Healing

#### 7.1 Placing occlusive dressing on sutured wounds

Sonia Lamel, Jie Li, and Robert S Kirsner

### 8. Wound Healing and Its Impact on Dressings and Postoperative Care

#### 8.1 Application of Apligraf

Yakir Levin, Katherine L Brown, and Tania J Phillips

#### 8.2 Application of Unna boot

Yakir Levin, Katherine L Brown, and Tania J Phillips

## PART II: Essential Surgical Skills

### 9. Electrosurgery

#### 9.1 Indirect electrodesiccation and direct electrodesiccation and electrofulguration

Ashish C Bhatia and Thomas E Rohrer

#### 9.2 Curettage and electrodesiccation

Ashish C Bhatia

#### 9.3 Direct electrodesiccation and indirect electrodesiccation and electrofulguration

Ashish C Bhatia

### 10. Cryosurgery

#### 10.1 Open technique

Paola Pasquali

#### 10.2 Tweezer technique

Paola Pasquali

#### 10.3 Human papillomavirus infection

Paola Pasquali

#### 10.4 Skin tags: treatment with tweezers

Paola Pasquali

#### 10.5 Seborrheic keratosis

Paola Pasquali

#### 10.6 Cherry angioma

Paola Pasquali

#### 10.7 Oral mucocoele

Paola Pasquali

#### 10.8 Myxoid cyst

Paola Pasquali

#### 10.9 Sebaceous hyperplasia

Paola Pasquali

#### 10.10 Actinic keratosis

Paola Pasquali

10.11 Control of freezing with high frequency ultrasound

*Paola Pasquali*

10.12 Superficial basal cell carcinoma

*Paola Pasquali*

## 11. Skin Biopsy Techniques

11.1 Curettage 1

*Andrew G Affleck*

11.2 Curettage 2

*Andrew G Affleck*

11.3 Punch biopsy 1

*Andrew G Affleck*

11.4 Punch biopsy 2

*Andrew G Affleck*

11.5 Excision of epidermoid cyst

*Andrew G Affleck*

11.6 Shave biopsy 1

*Andrew G Affleck*

11.7 Shave biopsy 2

*Andrew G Affleck*

11.8 Snip excisions

*Andrew G Affleck*

11.9 Elliptical incisional biopsy

*Andrew G Affleck*

## 12. Incision, Draining, and Exteriorization Techniques

12.1 Negative-pressure suction therapy

*Masato Yasuta*

## 13. Suturing Technique and Other Closure Materials

13.1 The simple interrupted, vertical mattress and running sutures

*Ashish C Bhatia*

13.2 Horizontal mattress stitches

*Divya Srivastava and R Stan Taylor*

13.3 Traditional buried – pulley

*Divya Srivastava and R Stan Taylor*

13.4 Buried vertical mattress suture technique

*Divya Srivastava and R Stan Taylor*

13.5 Buried butterfly

*Divya Srivastava and R Stan Taylor*

## 14. Complex Layered Facial Closures

14.1 Excision with intradermal suture

*Thomas E Rohrer*

14.2 Elliptical excision and layered repair

*Thomas E Rohrer*

14.3 Layered closure

*Ashish C Bhatia*

14.4 Rotation flap with suspension suture

*Thomas E Rohrer*

## 15. Hemostasis

15.1 Anesthesia with adrenaline and electronic scalpel

*Pedro Redondo*

15.2 Hemostasis in superficial procedures

*Pedro Redondo*

15.3 Hemostasis in skin surgery

*Pedro Redondo*

15.4 Jackson-Pratt drain

*Pedro Redondo*

## 16. Ellipse, Ellipse Variations, and Dog-ear Repairs

16.1 Elliptical excision

*Allison Hanlon and Samuel E Book*

16.2 S-plasty

*Thomas E Rohrer*

16.3 Dog-ear repair

*Thomas E Rohrer*

## 17. Random Pattern Cutaneous Flaps

17.1 Island pedicle flap

*Jonathan L Cook, Glenn D Goldman, and Todd E Holmes*

17.2 Rotation flap on the cheek/eyelid

*Jonathan L Cook, Glenn D Goldman, and Todd E Holmes*

17.3 Temple rhombic flap

*Jonathan L Cook, Glenn D Goldman, and Todd E Holmes*

17.4 Transposition flap

*Thomas E Rohrer and Ashish C Bhatia*

## 18. Axial Pattern Flaps

18.1 Division and inset of two-staged paramedian forehead flap

*Christopher J Miller and Joseph F Sobanko*

18.2 Primary inset of paramedian forehead flap and free cartilage graft

*Christopher J Miller and Joseph F Sobanko*

18.3 Abbe flap

*Christopher J Miller and Joseph F Sobanko*

18.4 Dorsal nasal rotation flap

*Christopher J Miller and Joseph F Sobanko*

## 19. Skin Grafting

19.1 Full-thickness skin graft

*Alvaro E Acosta*

19.2 Full-thickness skin graft

*Sumaira Z Aasi*

19.3 Split-thickness skin graft

*Alvaro E Acosta*

19.4 Conchal bowl graft to nose

*Thomas E Rohrer*

19.5 Placement of full-thickness human cadaveric allograft

*Ashish C Bhatia*

## 20. Acne Scar Revision

20.1 Botulinum toxin and hyaluronic acid filler to chin area

*Greg J Goodman*

20.2 Skin rolling, skin needling and Dermapen

*Greg J Goodman*

20.3 Fillers to scarring

*Greg J Goodman*

20.4 5-FU injection

*Greg J Goodman*

20.5 Subcision

*Greg J Goodman*

20.6 Fat transfer

*Greg J Goodman*

## 21. Revision of Surgical Scars

21.1 Scar revision via dermabrasion

*Neil A Swanson*

## PART III: Aesthetic Surgical Procedures

## 24. Soft-tissue Augmentation

24.1 Overview of fillers

*Ashish C Bhatia*

24.2 Restylane injection

*Thomas E Rohrer*

24.3 Radiesse injection

*Ashish C Bhatia*

24.4 Soft-tissue augmentation

*Roberta D Sengelmann*

## 25. Chemical Peels

25.1 Glycolic acid peel

*Cherie M Ditre*

*From Procedures in Cosmetic Dermatology Series: Chemical Peels, edited by Jeffrey S Dover. Copyright Elsevier 2010.*

25.2 Salicylic acid

*Pearl Grimes*

*From Procedures in Cosmetic Dermatology Series: Chemical Peels, edited by Jeffrey S Dover. Copyright Elsevier 2010.*

25.3 Modified phenol face peel – preparation

*Phillip A Stone*

*From Procedures in Cosmetic Dermatology Series: Chemical Peels, edited by Jeffrey S Dover. Copyright Elsevier 2010.*

- 25.4 Modified phenol face peel – peel application  
*Phillip A Stone*  
*From Procedures in Cosmetic Dermatology Series: Chemical Peels, edited by Jeffrey S Dover. Copyright Elsevier 2010.*
- 25.5 Modified phenol face peel – peel removal  
*Phillip A Stone*  
*From Procedures in Cosmetic Dermatology Series: Chemical Peels, edited by Jeffrey S Dover. Copyright Elsevier 2010.*
- 25.6 Deep peeling (Exoderm method)  
*Marina Landau and Sahar F Ghannam*
- 26. Implants**
- 26.1 Chin implants  
*J Michael Carney*
- 27. Botulinum Toxins**
- 27.1 Botulinum toxins  
*Doris Hexsel and Camile L Hexsel*
- 28. Liposuction**
- 28.1 Liposuction  
*Ashish C Bhatia and Michael S Kaminer*
- 28.2 Tumescent liposuction: tumescent anesthesia  
*Michael S Kaminer*
- 28.3 Tumescent liposuction: liposuction for breast reduction  
*Michael S Kaminer*
- 29. Autologous Fat Transfer: Evolving Concepts and Techniques**
- 29.1 FAMI procedure  
*Kimberly J Butterwick*
- 30. Follicular Unit Hair Transplantation**
- 30.1 Robotic follicular unit extraction (RFUE)  
*Robert M Bernstein*
- 30.2 Follicular unit transplantation (FUT)  
*Robert M Bernstein*
- 30.3 Hair transplantation  
*Walter Unger*
- 30.4 Follicular unit hair transplantation  
*Robert M Bernstein*
- 31. Laser Hair Removal**
- 31.1 Laser hair removal: hair removal IPL LHE Radiancy  
*Thomas E Rohrer*
- 32. Laser Treatment of Tattoos and Pigmented Lesions**
- 32.1 Treatment of lentigines  
*Thomas E Rohrer*
- 32.2 1550-nm fractional photothermolysis  
*Kenneth A Arndt and Emmy M Graber*
- 32.3 Arm tattoo removal by laser  
*Thomas E Rohrer*
- 32.4 Eye and lipliner tattoo removal by laser  
*Ashish C Bhatia and Thomas E Rohrer*
- 34. Laser-based Treatment of the Aging Face for Skin Resurfacing: Ablative and Non-ablative Lasers**
- 34.1 Fractional CO<sub>2</sub> scanner pattern  
*Ashish C Bhatia*
- 34.2 Ablative fractional skin resurfacing  
*Omar A Ibrahim and Suzanne L Kilmer*
- 34.3 Nonablative fractional skin resurfacing  
*Omar A Ibrahim and Suzanne L Kilmer*
- 34.4 Nonablative treatment of sebaceous hyperplasia  
*Omar A Ibrahim and Suzanne L Kilmer*
- 35. Laser and Light Treatment of Acquired and Congenital Vascular Lesions**
- 35.1 Treatment of portwine stain  
*Johnny Chun Yin Chan and Henry Hin Lee Chan*
- 35.2 IPL Ellipse treatment of facial telangiectasias on a patient with hereditary hemorrhagic telangiectasias  
*Agneta Troilius and Magnus B Nilsson*
- 36. Sclerotherapy of Varicose Veins**
- 36.1 Sclerotherapy for leg veins  
*Jeffrey T S Hsu*
- 37. Endovenous Ablation Techniques with Ambulatory Phlebectomy for Varicose Veins**
- 37.1 Radiofrequency segmental ablation and phlebectomy  
*Sanja Schuller-Petrović, Felizitas Pannier, and Miloš D Pavlović*
- 37.2 Endovenous laser ablation of saphenous veins  
*Sanja Schuller-Petrović, Felizitas Pannier, and Miloš D Pavlović*
- 38. Lamellar High-SMAS Minimum Incision Face Lift**
- 38.1 Minimum incision face lift  
*Robert C Langdon, Gerhard Sattler and C William Hanke*
- 39. Vertical Vector Face Lift with Local Anesthesia**
- 39.1 Tumescent face lift  
*Greg S Morganroth*
- 40. Blepharoplasty and Brow-lift**
- 40.1 Mid forehead brow-lift and upper eyelid laser-assisted blepharoplasty to correct bilateral brow ptosis and dermatochalasis  
*Alina Fratila*
- 40.2 UltraPulse CO<sub>2</sub> laser-assisted upper eyelid blepharoplasty  
*Alina Fratila*
- 40.3 Blepharoplasty in the Asian eye – Aesthetic archives  
*Robert S Flowers*  
*From Aesthetic Plastic Surgery, edited by Sherrell J Aston, Douglas S Steinbrech, and Jennifer L Walden. Copyright Elsevier 2010.*
- 40.4 Transconjunctival UltraPulse™ CO<sub>2</sub> laser-assisted lower eyelid blepharoplasty  
*Alina Fratila*
- 41. Rejuvenation of the Neck Using Liposuction and Other Techniques**
- 41.1 Neck liposuction: tumescent and laser-assisted  
*Michael S Kaminer*
- 41.2 Neck sling procedure  
*Michael S Kaminer and Ashish C Bhatia*
- 42. Rejuvenation of the External Female Genitalia**
- 42.1 Rejuvenation of the female external genitalia  
*Doris Hexsel*
- 
- PART IV: Special Procedures**
- 
- 43. Keloid Management**
- 43.1 Keloid management  
*David Ozog*
- 45. Mohs Micrographic Surgery and Cutaneous Oncology**
- 45.1 Mohs micrographic surgery  
*Developed by Tri H Nguyen MD and Michael R Migden MD, with support from Mayo Clinic*  
© 2005 – American College of Mohs Surgery.
- 46. Leg Ulcer Management**
- 46.1 Care for ankle ulcers over bony prominences using bolster material  
*Ysabel Bello, Carlos A Charles, Anna F Falabella, and Adolfo C Fernández-Obregón*

46.2 Care for medial ankle venous ulcers using foam material

*Ysabel Bello, Carlos A Charles, Anna F Falabella, and Adolfo C Fernández-Obregón*

46.3 Debridement of fibrous and necrotic material from ulcer

*Ysabel Bello, Carlos A Charles, Anna F Falabella, and Adolfo C Fernández-Obregón*

#### **48. Repair of the Split Earlobe, Ear Piercing, and Earlobe Reduction**

48.1 Partially split earlobe repair

*Ashish C Bhatia and Thomas E Rohrer*

48.2 Repair of the completely split earlobe

*Sirunya Silapunt and Leonard H Goldberg*

48.3 Ear piercing

*Sirunya Silapunt and Leonard H Goldberg*

#### **49. Hidradenitis suppurativa**

49.1 Procedural treatments of hidradenitis suppurativa

*Virginia J Reeder, David Ozog, and Iltefat Hamzavi*

### **PART V: Office-Based Surgery: Physical and Regulatory**

---

#### **51. Design of the Surgical Suite, Including Large Equipment, and Monitoring Devices**

51.1 Office walk-through

*Thomas E Rohrer*

# Preface

---

The first edition of *Surgery of the Skin: Procedural Dermatology* became known as the “Hand Book” because of the cover image of the editor’s hands. We are delighted that the text became the handbook of procedural dermatology. The second edition was regarded by our readers as their preferred concise ready reference, thus, earning the sobriquet of handbook. The book cover of each edition is created especially for that edition; therefore, we have retired two book covers focusing on hands. The first book cover was the image of the editor’s hands, and the second with images of our author’s hands performing procedures. With the aging of the population in many countries, more attention is being given to the appearance of the aging face. The cover of the third edition reflects this emphasis with the facial profile.

Dermatologic surgery has evolved over the last five years, and each of the chapters has been edited to reflect this. In addition, new chapters were added to present fully developed dermatologic surgery treatments for vitiligo, hidradenitis suppurativa and rejuvenation of the female external genitalia. Portions of each chapter are offered online as a part of the website called “Expert Consult.” The edited

online content provides additional examples of surgical cases with variations on the material presented in the textbook. Dermatologic surgeons frequently make choices between a variety of treatment options, e.g. medical vs. surgical treatment, chemical peeling vs. laser resurfacing, or flap vs. graft reconstruction. There are some regional and generational differences in physicians’ execution of commonly performed techniques as well as differences related to the racial/ethnic differences of the patient. Selecting among the variety of treatment options and their execution is part of the art of procedural dermatology. Each of our authors is an accomplished artist and we are indebted to them.

*June K Robinson, MD*  
*C William Hanke, MD, MPH, FACP*  
*Daniel M Siegel, MD, MS*  
*Alina Fratila, MD*

Video Editors  
*Ashish C Bhatia, MD, FAAD*  
*Thomas E Rohrer, MD*

# List of Contributors

**Sumaira Z Aasi MD**  
Director  
Mohs and Dermatologic Surgery  
Professor  
Stanford University  
Redwood City, CA, USA

**Alvaro E Acosta MD**  
Associate Professor  
National University of Colombia  
Director  
Dermatology & Oncology  
National Cancer Institute of Colombia  
Bogotá, Colombia

**Andrew G Affleck BSc(Hons), MBChB, MRCP**  
Consultant Dermatologist and Mohs Surgeon  
Department of Dermatology  
Ninewells Hospital and Medical School  
Dundee, UK

**Murad Alam MD, MSCI**  
Professor of Dermatology, Otolaryngology, and Surgery  
Chief, Section of Cutaneous and Aesthetic Surgery  
Director, Mohs Micrographic Surgery  
Northwestern University  
Chicago, IL, USA

**Sadegh Amini MD**  
Dermatology Resident  
Department of Dermatology and Cutaneous Surgery  
University of Miami Miller School of Medicine  
Miami, FL, USA

**Kenneth A Arndt MD**  
President  
SkinCare Physicians  
Chestnut Hill, MA  
Clinical Professor of Dermatology, Emeritus  
Harvard Medical School  
Boston, MA  
Adjunct Professor  
Department of Surgery  
Dartmouth Geisel School of Medicine  
Hanover, NH  
Adjunct Professor of Dermatology  
Brown University  
Providence, RI, USA

**Christopher J Arpey MD**  
Professor of Dermatology  
The C William Hanke Endowed Professor of Dermatologic Surgery  
Department of Dermatology  
University of Iowa, Carver College of Medicine  
Brooklyn, NY, USA

**Hilary Baldwin MD**  
Associate Professor of Clinical Dermatology  
Department of Dermatology  
State University of New York  
Brooklyn, NY, USA

**Ysabel Bello MD, CWS**  
Volunteer Faculty  
Dermatology Department  
University of Miami  
Miami, FL, USA

**Brian Berman MD, PhD**  
Co-Director  
Center for Clinical and Cosmetic Research  
Aventura  
Voluntary Professor of Dermatology and Cutaneous Surgery  
University of Miami Miller School of Medicine  
Miami, FL, USA

**Robert M Bernstein MD, MBA, FAAD**  
Clinical Professor  
Department of Dermatology  
College of Physicians and Surgeons  
Columbia University  
New York, NY, USA  
Founder  
Bernstein Medical – Center for Hair Restoration  
New York, NY, USA

**Ashish C Bhatia MD, FAAD**  
Associate Professor of Clinical Dermatology  
Department of Dermatology  
Northwestern University – Feinberg School of Medicine  
Chicago, IL USA  
Medical Director for Dermatologic Research, DuPage Medical Group  
Chairman, Department of Dermatology, DuPage Medical Group  
Co-Director of Dermatologic, Laser & Cosmetic Surgery  
The Dermatology Institute,  
Naperville, IL, USA

**Diana Bolotin MD, PhD**  
Assistant Professor  
Director of Dermatologic Surgery  
Section of Dermatology  
University of Chicago  
Chicago, IL, USA

**Samuel E Book MD, FAAD**  
Clinical Assistant Professor  
Section of Dermatologic Surgery and Cutaneous Oncology  
Department of Dermatology  
Yale University School of Medicine  
New Haven, CT, USA

**Andrew Breithaupt MD**  
Dermatology Resident  
Division of Dermatology  
David Geffen School of Medicine at UCLA  
Los Angeles, CA, USA

**Franz X Breu MD**  
Private Practice  
Rottach-Egern, Tegernsee, Germany

**Katherine L Brown MD, MPH**  
Dermatologist  
Gulf Coast Dermatology  
Jacksonville, FL, USA

**Kimberly J Butterwick MD**  
Dermatologist/Cosmetic Surgeon  
Cosmetic Laser Dermatology  
Goldman Butterwick Fitzpatrick  
Groff & Fabi  
San Diego, CA, USA

**Theresa Cao DO**  
Assistant Professor, Clinical Department of Dermatology and Cutaneous Surgery  
University of Miami Miller School of Medicine  
Miami, FL, USA

**J Michael Carney MD**  
Adjunct Clinical Associate Professor  
University of Arkansas for Medical Sciences  
Little Rock, AR, USA

**Todd V Cartee MD**  
Assistant Professor of Dermatology  
Penn State Hershey Medical Center  
Hershey, PA, USA

**Henry Hin Lee Chan MBBS, MD, PhD, FRCP, FHKCP, FHKAM**  
Hon Clinical Professor  
Division of Dermatology  
Department of Medicine  
Li Ka Shing Faculty of Medicine  
The University of Hong Kong  
Hong Kong

**Johnny Chun Yin Chan MBBS, MRCP, FHKCP, FHKAM**  
Clinical Assistant Professor  
Division of Dermatology  
Department of Medicine  
Li Ka Shing Faculty of Medicine  
The University of Hong Kong  
Pokfulam, Hong Kong

**Carlos A Charles MD**  
Founding Director  
Derma di Colore  
New York, NY, USA  
Clinical Instructor  
Weill Cornell Medical College  
Department of Dermatology  
New York, NY, USA

**Cameron Chesnut MD**  
Procedural Dermatology Fellow  
Division of Dermatology  
David Geffen School of Medicine at UCLA  
Los Angeles, CA, USA

**Graham Colver BM, BCh, DM, FRCP**  
Consultant Dermatologist  
Division of Dermatology  
Chesterfield Royal Hospital



**Jonathan L Cook MD**

Professor of Dermatology  
Assistant Professor of Surgery  
Duke University Medical Center  
Durham, NC, USA

**Nicholas B Countryman MD MBA**

Volunteer Assistant Professor of Clinical  
Dermatology  
Department of Dermatology, Indiana University  
School of Medicine  
Staff Dermatologist  
Department of Dermatology  
St Vincent Hospital  
Indianapolis, IN, USA

**Lisa M Donofrio MD**

Associate Clinical Professor  
Dermatology  
Yale University School of Medicine  
New Haven, CT, USA

**Anna F Falabella MD, CWS**

Voluntary Associate Professor  
Department of Dermatology and Cutaneous  
Surgery  
University of Miami Miller School of Medicine  
Miami, FL, USA

**Adolfo C Fernández-Obregón MD, FAAD, FACP**

Assistant Clinical Professor  
Department of Dermatology  
New York Medical College  
New York, NY, USA  
Hudson Dermatology & Skin Cancer Center  
Hoboken, NJ, USA

**Edgar F Fincher MD, PhD**

Moy-Fincher-Chipps Facial Plastic, Dermatology  
Dermatologic and Cosmetic Surgery  
Beverly Hills, CA, USA

**Alina Fratila MD**

Medical Director  
Jungbrunnen-Klinik Dr. Fratila GmbH  
Bonn, Germany  
Associate Professor  
Victor Babes University of Medicine and  
Pharmacy  
Timisoara, Romania

**Sahar F Ghannam MD, PhD**

Consultant of Dermatology, Venereology,  
Cosmetic Dermatology and Laser  
Kuwait  
Associated Professor, Alexandria University  
Alexandria, Egypt

**Hayes B Gladstone MD**

Berman Gladstone Skin Institute  
Palo Alto, CA, USA

**Dee Anna Glaser MD FAAD**

Professor of Dermatology  
Director of Cosmetic and Laser Surgery  
Vice Chairman, Department of Dermatology  
St Louis University  
St Louis, MO, USA

**Leonard H Goldberg MD, FRCP**

Clinical Professor  
Weill Medical College of Cornell University  
The Methodist Hospital  
Houston, TX, USA

**Glenn D Goldman MD**

Chief of Dermatology  
Director of Dermatologic Surgery  
Fletcher Allen Health Care  
The University of Vermont College of Medicine  
Burlington, VT, USA

**Anne Goldsberry MD, MBA**

Procedural Dermatology Fellow  
Laser and Skin Surgery Center of Indiana  
Carmel, IN, USA

**Greg J Goodman MD, FACD**

Associate Professor, Monash University  
Clayton, Victoria  
Head of Surgery, Skin and Cancer Foundation of  
Victoria  
Carlton, Victoria, Australia

**Hubert T Greenway MD**

CEO Emeritus  
Director of Cutaneous Oncology  
Division of Mohs Surgery  
Scripps Clinic  
La Jolla, CA, USA

**Iltefat Hamzavi MD**

Senior Staff Physician  
Department of Dermatology  
Henry Ford Medical Center  
Clinical Assistant Professor  
Wayne State University, SOM  
Detroit, MI, USA

**Eckart Haneke MD, PhD**

Professor of Dermatology  
Senior Consultant in Dermatology  
Inselspital  
University of Bern  
Bern, Switzerland  
Dermatologist  
Dermaticum Freiburg  
Freiburg, Germany  
Visiting Professor  
Centro de Dermatología  
Instituto CUF  
Porto, Portugal  
Visiting Professor  
Dermatology  
Academic Hospital University of Ghent  
Ghent, Belgium

**C William Hanke MD MPH FACP**

Visiting Professor of Dermatology  
University of Iowa, Carver College of Medicine  
Iowa City, Iowa  
Clinical Professor of Otolaryngology, Head and  
Neck Surgery  
Indiana University School of Medicine  
Indianapolis, IN, USA

**Allison Hanlon MD, PhD**

Nashville Skin and Cancer  
Nashville, TN, USA

**Camile L Hexsel MD**

Dermatologic Surgeon  
Investigator  
Brazilian Center for Studies in Dermatology  
Porto Alegre, RS, Brazil  
ProHealth Care Medical Associates  
Waukesha County, WI, USA

**Doris Hexsel MD**

Dermatologist and Dermatologic Surgeon  
Department of Dermatology  
Pontificia Universidade Catolica do Rio Grande do  
Sul  
Brazilian Center for Studies in Dermatology  
Porto Alegre, Rio Grande do Sul, Brazil

**Todd E Holmes MD**

Associate Professor  
Division of Dermatology  
Fletcher Allen Health Care  
University of Vermont College of Medicine  
Burlington, VT, USA

**George J Hruza MD, MBA**

Clinical Professor of Dermatology and  
Otolaryngology  
St Louis University  
St Louis, MO, USA  
Medical Director  
Laser and Dermatologic Surgery Center  
Chesterfield, MO, USA

**Jeffrey T S Hsu MD FAAD**

Adjunct Assistant Professor in Dermatology  
Dartmouth Medical School  
Naperville, IL, USA

**Omar A Ibrahim MD, PhD**

Founding Director  
Connecticut Skin Institute  
Stamford, CT  
Visiting Scientist  
Wellman Center for Photomedicine  
Massachusetts General Hospital  
Harvard Medical School  
Boston, MA, USA

**Scott N Isenhardt MD**

Director, Mohs and Dermatologic Surgery  
Group Health Cooperative  
Seattle, WA, USA

**Vivek Iyengar MD**

Clinical Associate Professor  
Section of Dermatology  
University of Chicago  
Chicago, IL, USA

**Michael S Kaminer MD**

Assistant Professor of Dermatology  
Yale and Dartmouth Medical Schools  
SkinCare Physicians of Chestnut Hill  
Chestnut Hill, MA, USA

**Amor Khachemoune MD**

Attending Physician  
Veterans Affairs Medical Center  
Brooklyn  
Director of Mohs Micrographic Surgery at  
Dermatology Associates  
Staten Island, NY, USA

**Niti Khunger MD, DDV, DNB**

Consultant Dermatologist & Professor  
Department of Dermatology & Sexually  
Transmitted Diseases  
Vardhman Mahavir Medical College  
Safdarjang Hospital  
New Delhi, India

**Suzanne L Kilmer MD**

Founding Director  
Laser & Skin Surgery Center of Northern  
California  
Clinical Professor  
Department of Dermatology  
UC Davis Medical Center  
Sacramento, CA, USA

**Young Kyoon Kim MD**

Director  
5050clinic  
Bucheon, South Korea  
Clinical Professor  
Chosun University Medical School  
Gwangju, South Korea  
Professor  
Korean College of Cosmetic Surgery  
Busan, South Korea

**Robert S Kirsner MD, PhD**

Vice Chairman  
Department of Dermatology and Cutaneous  
Surgery  
University of Miami Miller School of Medicine  
Miami, FL, USA

**Koushik Lahiri MBBS, DVD, FIAD, FFAADV, FAAD, MRCPs**

Consultant Dermatologist  
Apollo Gleneagles Hospitals and Wizdorm  
Kolkata, India

**Sonia Lamel MD**

Dermatology Resident  
Department of Dermatology  
New York Medical College  
New York, NY, USA

**Marina Landau MD**

Dermatology  
Wolfson Medical Center  
Holon, Israel

**Robert Lane BS**

Medical Student  
University of Tennessee  
College of Medicine  
Memphis, TN, USA

**Robert C Langdon MD**

Clinical Associate Professor of Dermatology  
Yale University School of Medicine  
New Haven, CT, USA

**Naomi Lawrence MD**

Director, Procedural Dermatology  
Cooper University Hospital  
Center for Dermatologic Surgery  
Marlton, NJ, USA

**William Lear MD**

Director of Dermatological Surgery  
Silver Falls Dermatology  
Corvallis and Salem, OR, USA

**Ken K Lee MD**

Affiliate Associate Professor of Dermatology  
Oregon Health & Science University  
Portland, OR, USA

**David J Leffell MD**

David Paige Smith Professor of Dermatology and  
Surgery  
Chief, Section of Dermatologic Surgery and  
Cutaneous Oncology  
Department of Dermatology  
Yale University School of Medicine  
New Haven, CT, USA

**Justin J Leitenberger MD**

Assistant Professor  
Department of Dermatology and Dermatologic  
Surgery  
Oregon Health & Science University  
Portland, OR, USA

**Yakir Levin MD, PhD**

Resident Physician  
Department of Dermatology  
Boston University Medical Center  
Boston, MA, USA

**Ross M Levy MD**

Assistant Director  
Dermatologic Surgery Unit  
North Shore University Health System  
Clinician Educator, Pritzker School of Medicine  
University of Chicago  
Chicago, IL, USA

**Jie Li MD, PhD**

Associate Professor  
Department of Dermatology and Cutaneous  
Surgery  
University of Miami Miller School of Medicine  
Miami, FL, USA

**Robert J MacNeal MD**

Assistant Professor  
Department of General Internal Medicine  
Dartmouth-Hitchcock Medical Center  
Lebanon, NH, USA

**Kurt L Maggio MD**

Director  
Cutaneous Laser Center  
Walter Reed Army Medical Center  
Washington DC, USA

**Kavita Mariwalla MD**

Assistant Professor  
Department of Dermatology  
SUNY at Stony Brook  
East Setauket, NY, USA  
Private Practice  
Mariwalla Dermatology  
West Islip, NY, USA

**Michael J Messingham MD**

Private Practice  
Accredited Dermatology Associates PC  
Davenport, IA, USA

**Christopher J Miller MD**

Assistant Professor of Dermatology  
Director of Dermatologic Surgery  
Department of Dermatology  
Hospital of the University of Pennsylvania  
Philadelphia, PA, USA

**Greg S Morganroth MD**

CEO and Founder  
California Skin Institute  
Mountain View, CA, USA

**Ronald L Moy MD, FAAD**

Professor  
David Geffen School of Medicine at The  
University of California  
Los Angeles, CA, USA

**Venkataram Mysore MD, DNB, DipRCPath, FRCP**

Director  
Venkat Charimalaya Centre for Advanced  
Dermatology and Postgraduate Training  
Bangalore, India

**Se Young Na PhD, MD**

Fellow  
Department of Dermatology  
Seoul National University Bundang Hospital  
Seongnam, Republic of Korea

**Shari Nemeth Ochoa MD, MS**

Chair of Dermatology Surgery  
Department of Dermatology  
Assistant Professor of Dermatology  
Department of Dermatology  
Mayo Clinic  
Scottsdale, AZ, USA

**Magnus B Nilsson**

Photographer  
Department of Plastic and Reconstructive Surgery  
Malmö University Hospital  
Malmö, Sweden

**Tri Nguyen MD, FACMS, FAAD, FACPh**

Northwest Diagnostic Clinic  
Mohs & Dermatology Associates  
Houston, TX, USA

**David Ozog MD, FAAD**

Director of Cosmetic Dermatology  
Vice-Chair of Operations  
Division of Mohs and Dermatological Surgery  
Department of Dermatology  
Henry Ford Medical Center  
Detroit, MI, USA

**Felizitas Pannier MD, Ass Prof**

Department of Dermatology, University of  
Cologne  
Cologne, Germany  
Vein Centre Bonn,  
Bonn, Germany

**Kyoung Chan Park MD, PhD**

Professor  
Department of Dermatology  
Seoul National University Bundang Hospital  
Seongnam, Republic of Korea

**Paola Pasquali MD**

Coordinator  
Dermatology Department  
Pius Hospital de Valls  
Tarragona, Spain



**Miloš D Pavlović MD, PhD**  
 Associated Professor of Dermatology  
 Medical University of Maribor  
 DCP – VENEX Vein Centre  
 Ljubljana, Slovenia

**Tania J Phillips MD, FRCPC**  
 Professor of Dermatology  
 Boston University School of Medicine  
 Boston, MA, USA

**Sebastian Pop MD**  
 Dermatologist and Dermatologic Surgeon  
 Medical Director  
 Dr Sebastian Dermatologie – Dermatologic and  
 Cosmetic Surgery Clinic  
 Bucharest, Romania

**Rachel N Pritzker MD**  
 Private Practice  
 Chicago Cosmetic Surgery and Dermatology  
 Clinical Instructor, John H. Stroger Jr. Hospital of  
 Cook County  
 Chicago, IL, USA

**Eberhard Rabe MD, Prof**  
 Professor of Dermatology  
 Department of Dermatology  
 University of Bonn  
 Bonn, Germany

**Pedro Redondo MD, PhD**  
 Professor of Dermatology  
 Department of Dermatology  
 University Clinic of Navarra  
 Pamplona, Navarra, Spain

**Virginia J Reeder MD**  
 CS Livingood Clinical Research Fellow  
 Department of Dermatology  
 Henry Ford Medical Center  
 Detroit, MI, USA

**June K Robinson MD**  
 Professor of Clinical Dermatology  
 Department of Dermatology  
 Northwestern University, Feinberg School of  
 Medicine  
 Chicago, IL, USA

**Thomas E Rohrer MD**  
 Associate Clinical Professor of Dermatology  
 Brown University School of Medicine  
 Providence, RI, USA  
 Private Practice  
 SkinCare Physicians  
 Chestnut Hill, MA, USA

**Antonio Rusciani MD, PhD**  
 Plastic Surgeon and Dermatologist  
 Director of Plastic Surgery  
 Division of Skinlaser Center of Rome  
 Rome, Italy

**Berthold Rzany MD, ScM**  
 Rzany & Hund  
 Berlin, Germany

**Nazanin Saedi MD**  
 Assistant Professor  
 Director  
 Laser Surgery and Cosmetic Dermatology  
 Department of Dermatology and Cutaneous  
 Biology  
 Thomas Jefferson University  
 Philadelphia, PA, USA

**Carmen Salavastru MD, PhD**  
 Professor  
 Second Department of Dermatology  
 Colentina Clinical Hospital  
 Carol Davila University of Medicine and  
 Pharmacy  
 Bucharest, Romania

**Gerhard Sattler MD**  
 Medical Director  
 Rosenparkklinik  
 Darmstadt, Germany

**Sanja Schuller-Petrović MD, PhD**  
 Director, VENEX Vein Centre  
 Vienna, Austria  
 Associate Professor of Dermatology  
 Medical University of Graz  
 Graz, Austria

**Rafael A Schulze MD**  
 Mohs Surgeon  
 Private Practice  
 Florida, USA

**Daniel M Siegel MD MS**  
 Clinical Professor of Dermatology  
 Department of Dermatology  
 SUNY Downstate Medical Center  
 College of Medicine  
 Brooklyn, NY, USA  
 Senior Surgeon  
 Long Island Skin Cancer and Dermatologic  
 Surgery, a division of ProHEALTH Care  
 Associates  
 Smithtown, NY, USA

**Sirunya Silapunt MD, RPhS**  
 Assistant Professor  
 Department of Dermatology  
 University of Texas Health Science Center at  
 Houston  
 Houston, TX, USA

**Joseph F Sobanko MD**  
 Assistant Professor of Dermatology  
 Director of Dermatologic Surgery Education  
 Hospital of the University of Pennsylvania  
 Philadelphia, PA, USA

**Brian Somoano MD**  
 Dermatology and Dermatologic Surgery  
 St Jude Heritage Medical Group  
 Fullerton, CA, USA

**Teresa T Soriano MD**  
 Associate Clinical Professor  
 Division of Dermatology  
 David Geffen School of Medicine at UCLA  
 Los Angeles, CA, USA

**Divya Srivastava MD**  
 Assistant Professor  
 Department of Dermatology  
 UT Southwestern Medical Center  
 Dallas, TX, USA

**William G Stebbins MD**  
 Assistant Professor of Dermatology  
 Director of Cosmetic Dermatology  
 Vanderbilt University Medical Center  
 Nashville, TN, USA

**Neil A Swanson MD**  
 Professor and Former Chair of Dermatology  
 Professor, Departments of Surgery and  
 Otolaryngology  
 Oregon Health and Sciences University  
 Portland, OR, USA

**R Stan Taylor MD**  
 Professor  
 Department of Dermatology  
 UT Southwestern Medical Center  
 Dallas, TX, USA

**Emily P Tierney MD**  
 Assistant Professor of Dermatology and  
 Mohs Micrographic Surgery  
 Department of Dermatology  
 Boston University School of Medicine  
 Boston, MA, USA

**Christie R Travelute MD**  
 Associate Professor of Dermatology  
 Penn State Hershey Medical Center  
 Hershey, PA, USA

**Agneta Troilus MD, PhD**  
 Associate Professor and Head  
 Laser & Vascular Anomaly Section  
 Department of Dermatology  
 Skåne University Hospital  
 Malmö, Sweden

**Sandy S Tsao MD**  
 Assistant Professor of Dermatology  
 Harvard Medical School  
 Laser and Cosmetic Dermatology  
 Massachusetts General Hospital  
 Boston, MA, USA

**Walter Unger MD**  
 Clinical Professor  
 Department of Dermatology  
 Mount Sinai School of Medicine  
 New York, NY  
 Associate Professor (Dermatology)  
 University of Toronto  
 Private Practice  
 New York, NY, USA  
 Toronto, ON, Canada

**Allison T Vidimos RPh, MD, FAAD, FACMS**  
 Chairman and Professor, Department of  
 Dermatology  
 Vice Chairman, Dermatology and Plastic Surgery  
 Institute  
 Cleveland Clinic  
 Cleveland, OH, USA

**Mara C Weinstein MD**  
 Dermatology Resident  
 Dermatology and Plastic Surgery Institute  
 Cleveland Clinic  
 Cleveland, OH, USA

**Masato Yasuta MD, PhD**  
 Assistant Professor  
 Department of Dermatology, Division of Plastic  
 and Reconstructive Surgery  
 University of Fukui  
 Fukui, Japan

# Dedication

---

To William T Barker, my husband, whose unwavering support has sustained me over the years, and the patients, medical students, dermatology residents, research associates and faculty of the Department of Dermatology at Northwestern University Feinberg School of Medicine, who challenge my assumptions and help me grow as a physician.

June K Robinson, MD

To my daughters, Sarah and Katherine, my sons, David and Peter, and to my wife, Margaret, whose support, love and friendship continues to guide my life.

C William Hanke, MD MPH FACP

To my wife Susan, for supporting the ongoing journey and the students, residents and fellows who keep me on my toes.

Daniel Mark Siegel, MD MS

To the loving memory of my beloved parents Marcela and Dr Alexandru Fratila. I would also like to thank Wolfgang Bramer, who has been a supportive friend throughout the fifty years we have worked together.

Alina Fratila, MD

To my wife, Margot, and my children, Harrison, Sam, and Emma for their constant influx of energy, support, and love. To my parents, Marilyn and Bob, for their unending love and support, and for infusing me with a sense of curiosity and exploration.

And to my colleagues, partners, and patients, for continually educating me.

Thomas E Rohrer, MD

My sincere gratitude goes to my mother, father, brothers and especially to my ever patient wife Tania for supporting my career and continuing to guide and inspire me every day.

I also thank my teachers, Bob Brodell and my fellowship directors in Chestnut Hill, MA for shaping my career and preparing me for the adventures ahead.

Many thanks go to my wonderful partners in practice, Jeff and Kelly, as well as our amazing team, who make it possible to have a fulfilling private practice as well as a research and academic career.

Ashish C Bhatia MD FAAD

# Acknowledgments

---

The editors are grateful to the amazing people who made this third edition a reality. These dedicated people helped us to achieve our goal of tapping the wealth of knowledge and experience of international experts in surgery of the skin.

First, we are indebted to the contributors who expended considerable time and effort in completing their chapters and sharing their experience in print and video formats.

Second, the editors and contributors have shifted personal time away from families and friends to complete their work.

Third, the United Kingdom publishing team has consistently been a pleasure to work with as we have sent emails around the globe at all hours of the day and night. Hats off to: Russell Gabbedy, Executive Content Strategist; Poppy Garraway and Samuel Crowe, Content Development Specialists.

# Anatomy for Procedural Dermatology

June K Robinson MD

1

## CHAPTER SUMMARY

- Wound healing and the final surgical result depend on the anatomic location, structure of the skin and its functional interaction with underlying elements of the region.
- Anticipation of the dynamic tension exerted on free margins of the eyelid, nasal rim, helix of the ear, and lip helps in planning the procedure to preserve the regional anatomy.
- The cosmetic units of the face and skin tension lines are used to plan a procedure.
- Knowledge of the sensory nerves is necessary for effective regional nerve blocks.
- The depth of the initial incision, the proper level of undermining, and placement of sutures depend on knowledge of the underlying anatomy.
- Knowledge of the regional anatomy and its drainage by the lymphatic system is important for assessment of melanoma, squamous cell carcinoma, and other aggressive cutaneous malignancies.

## INTRODUCTION

Feeling comfortable with regional anatomy promotes competency in performing surgical procedures. Regional anatomy is integrated into chapters when understanding the anatomy is relevant to the surgical procedure. For example, the superficial musculoaponeurotic system (SMAS) is described in the chapter discussing layered facial closures with plication of the SMAS ([Chapter 14](#)). In some instances, the topographic anatomy is provided only in the chapter with the surgery of the specialized unit. For example, nail unit surface topography and anatomy of the distal phalanx are provided with nail surgery ([Chapter 47](#)); and the anatomy of the superficial and deep venous system of the leg is with sclerotherapy for leg veins ([Chapter 36](#)). Regional topographic anatomy that is not included in other chapters is provided in this chapter, thus the terminology used to describe surface features of the ear, nose, lips, genitalia, hands, and feet is included in this chapter. A figure from this chapter may be repeated in subsequent chapters in order to inform the description of the surgical procedure. For example, the topographic landmarks and components of the periorbital region are included in the description of blepharoplasty.

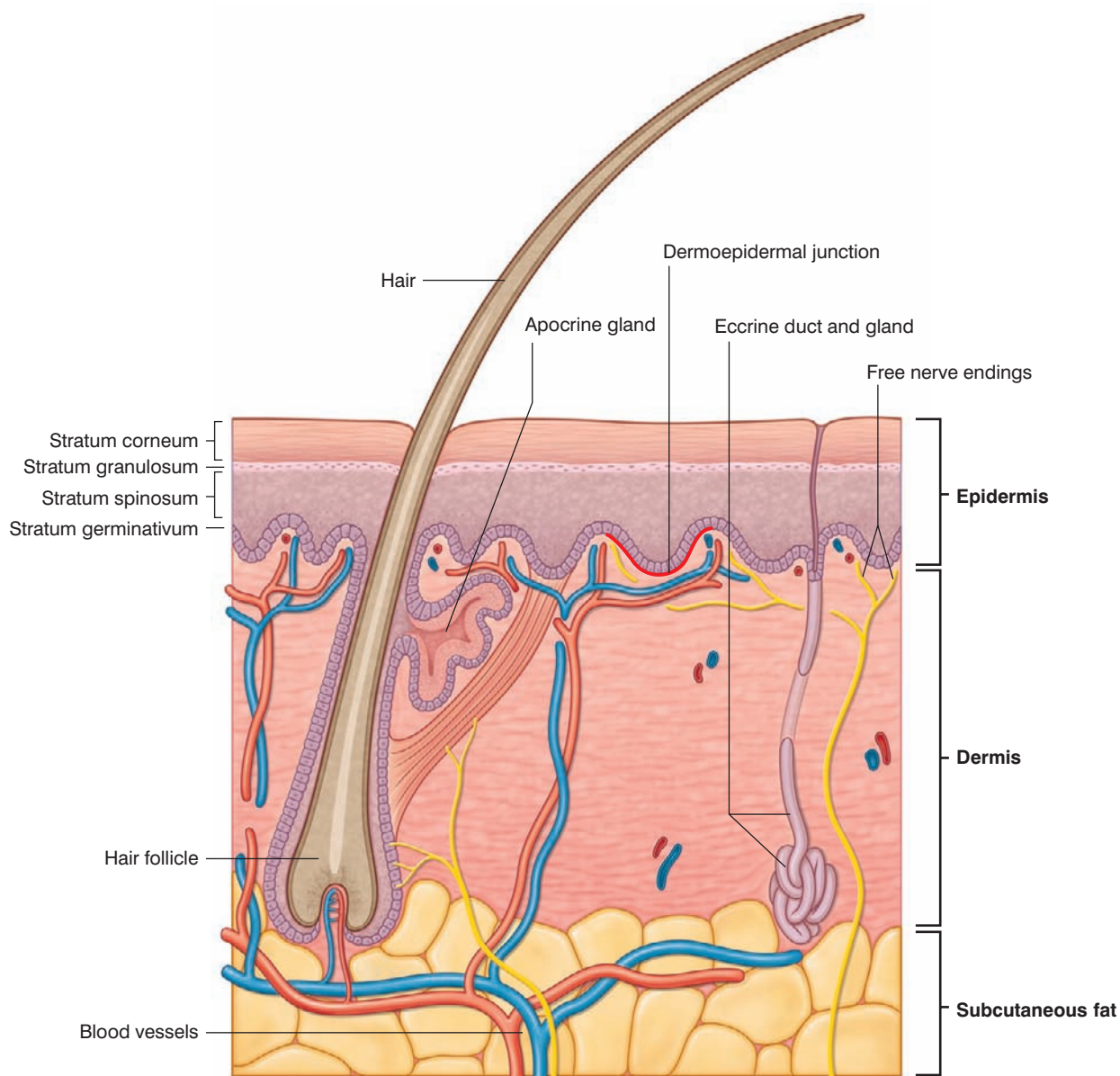
Planning surgical procedures depends upon a working knowledge of anatomy. The decision to perform surgery requires assessment of the risks and benefits of the procedure for the individual patient. The anticipated final appearance is, in part, determined by the regional anatomy and the functional interaction of the skin with underlying anatomic features. The cosmetic units of the face; location of free margins of the eyelid, nasal rim, helix of the ear, and lip; and skin tension lines are used to plan the procedure. In addition, flaps are designed to prevent persistent post-operative lymphedema. Providing safe and sufficient anesthesia requires knowledge of the sensory nerves to allow for effective regional nerve blocks. Superficial topography, also known as the surface landmarks, is used to locate underlying blood vessels, sensory and motor nerves, and lymphatic ducts. The level of undermining used to mobilize tissue requires an understanding of the horizontal arrangement of the cutaneous, muscular, and fascial soft tissue planes. Suture placement requires both vertical and horizontal orientation to the tissue. It is critically important to know the drainage pattern of the lymphatic system, which must be examined for cutaneous metastasis of melanoma, squamous cell carcinoma, and other aggressive cutaneous malignancies.

## SKIN STRUCTURE AND FUNCTIONAL BIOMECHANICS

While most of the skin's biomechanical properties are derived from dermal collagen and elastin, the subcutaneous fat, blood vessels, and nerves play a role in the skin's functional biomechanics. While the epidermis has almost no biomechanical role, the dermoepidermal junction is important to wound healing ([Fig. 1.1](#)).

### Epidermis

The outermost layer of the skin, the epidermis, is a continuous self-regenerating layer of stratified squamous epithelium varying in thickness from 0.04 mm on the eyelids and genitalia, to 1.5 mm on the palms and soles.<sup>1</sup> The stratum germinativum, or basal cell layer, is composed of a single row of columnar epithelial cells arranged with their long axes perpendicular to the dermoepidermal junction. The basal keratinocytes are the active stem cells that proliferate



**FIGURE 1.1** Skin consists of three major divisions: epidermis, dermis, and subcutaneous fat. (After White CR, Bigby M, Sanguenza OP. What is normal skin? In: Arndt KA, LeBoit PE, Robinson JK, Wintroub BU, eds. *Cutaneous medicine and surgery*. Philadelphia: Saunders; 1996:3–41.)

heterogeneously and maintain homeostasis by balancing proliferation (S phase) and non-cycling (G0, G1, G2 phase) cells. Non-cycling stem cells can be recruited by wounding.

While there may be differences from one person to another for eyelid skin, the thickness of the facial skin of any one person may be expressed as how many times thicker it is than eyelid skin. For example, nasal tip skin is 3.30 times thicker than eyelid skin, the nasal dorsum is 2.92 times thicker, and the brow/forehead is 2.8 times thicker.<sup>2</sup> This ratio uses the epidermal and dermal thickness of eyelid skin as the reference unit for comparison. Skin thickness varies with age, race, gender, and the degree of photodamage. An understanding of the relative thickness

of the skin helps the surgeon closely approximate the original characteristics of the skin when planning a repair.

## Dermis

The dermis is a flexible, intricate, connective tissue network of collagen and elastin fibers embedded in a ground substance matrix that accommodates nerve bundles, sensory receptors, lymphatic channels, and vasculature. Beneath the dermoepidermal junction, collagen, especially collagen type I, constitutes 75% of the dermis.<sup>3</sup> In the adventitial and papillary dermis, collagen fibers are loosely arranged and form a fine meshwork, whereas in the reticular dermis, they are assembled into thick interwoven bundles. Elastic



fibers constitute approximately 3% of the dermis by dry weight, measure 1–3 mm in diameter, and play a major role in skin elasticity and resilience.<sup>4</sup> Elastic fibers are confined to the lower portion of the dermis, where they are arranged parallel to the epidermis. The third component of the dermis is the ground substance, an amorphous material that fills spaces between the fibrillar and cellular components of the dermis, imparting turgidity and resilience. In human skin, the dermal matrix consists of glycosaminoglycans (hyaluronic acid and dermatan sulfate) and glycoproteins. Fibronectin, the major filamentous glycoprotein component of the dermal matrix, is produced by fibroblasts. Fibronectin ensheathes collagen and elastin bundles and plays a role in the attachment of keratinocytes to the basal lamina, which is important in wound healing.

### Intrinsic elasticity

The intrinsic elasticity of the skin, its “stretchability,” is an important characteristic to understand during wound closure. In areas where the dermis is relatively inflexible and lacks elasticity (back, scalp), even small degrees of tissue rotation may result in protrusion of the pivot point, whereas in areas where the skin possesses significant elasticity (young facial skin), larger angles of rotation are absorbed without causing protrusion. Lifting and stretching the skin between the surgeon’s index finger and thumb is a helpful means for estimating the elasticity of the skin before wound reconstruction.

In comparison with static materials such as steel, skin’s stress–strain relationship varies over time and is not a linear relationship (Fig. 1.2). Intrinsic tissue elasticity is related to the patient’s age, amount of photodamage, and anatomic site. In general, younger patients possess greater tissue elasticity for a given anatomic site than older patients. Markedly photodamaged skin possesses less elasticity than photoprotected skin. In some anatomic sites, such as the back of the hand or elbow, the skin is easily movable

but quite inelastic. In inelastic skin such as the scalp, even a 30° angle of closure may produce noticeable tissue protrusion.

### Biomechanical skin responses

Biomechanical properties determine the tissue response to intraoperative conditions. These properties are measured by stress, elasticity, creep, and stress relaxation. Stress (load) can be defined as force delivered to a cross-sectional area. Strain is the change in length in comparison to the original length.<sup>6</sup> The load versus length relationship is the stress–strain curve (Fig. 1.2). During the initial stages of loading, the material deforms in direct proportion to the stress, as seen by the early straight-line relation between stress and strain. The slope of this curve up to point A, the elastic region of the stress–strain curve, is Young’s modulus or the modulus of elasticity (E).<sup>5,6</sup> The equation of this line, Hooke’s law, is  $\sigma = Ee$ , where  $\sigma$  is defined as stress and  $e$  is defined as strain. Materials with larger E values are stiffer or more rigid than those with low E values.

A material loaded with stress beyond point A will not completely return to its original shape after removal of the stress. Point A represents the elastic limit. Loading beyond point A produces permanent deformation; this region of the curve is the plastic region. As the stress is removed, the elastic portion recovers along a line parallel to the original slope (Fig. 1.2, dashed line), leaving permanent deformation. The limit of usable elastic behavior is defined as point B, the yield strength. As loading continues into the plastic region, the increasing stress does produce increasing strain, but not in a linear fashion (Fig. 1.2, points B and C). The specimen elongates on continued application of the load until the point is reached at which the specimen is unable to adapt enough to continue to support the load (Fig. 1.2, point C, tensile strength). The region from B to C demonstrates that the stretchability of skin is non-linear. Stress relaxation most likely occurs because of breakage of collagen fibers. After the maximal load is exceeded, the specimen elongates rapidly and rupture occurs (Fig. 1.2, point D). Obviously, during intraoperative loading of the skin, the surgeon seeks to maximize the stress to produce the greatest strain that can be tolerated by the skin. Thus the region of this curve BC must be used to optimal advantage, but the load should not exceed the tensile strength of the skin or the tissue will slip into the portion of the curve CD that leads to rupture.

Movement of the skin is characterized by its ability to stretch over time (creep). Mechanical creep occurs when the skin is stretched at a constant force and eventually contributes to skin deformation. The constant force results in extrusion of tissue fluid from the interstices of the collagen network and stretching of skin beyond its inherent extensibility. The stretching achieved during mechanical creep does not retract intraoperatively. At a certain point in the stress–strain curve, there is almost complete relaxation (stress relaxation), which is most likely because of the breakage of collagen fibers; however, after this point,

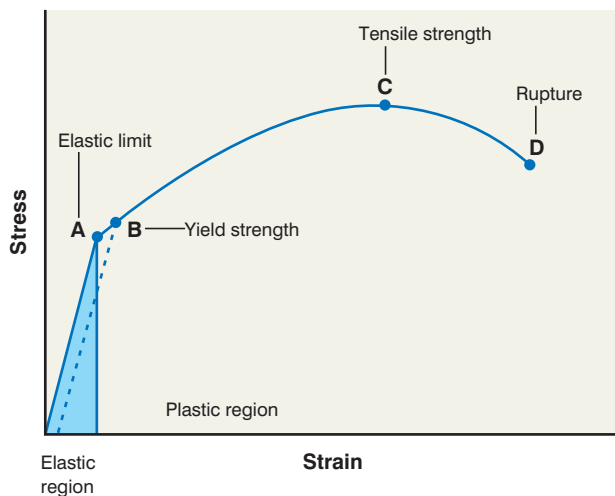


FIGURE 1.2 The stress–strain relationship. (After Marcus et al. 1990,<sup>5</sup> with permission from Journal of the American Academy of Dermatology Inc.)

additional undermining will not reduce closure tension, but will increase the risk of hematomas or nerve damage.

Closing a wound without tension can be achieved by intraoperative loading with a constant force, such as placing temporary retention sutures (pulley stitch) for about 15 min. Another way of achieving mechanical creep is by load cycling, which is performed with strong traction exerted with skin hooks at 3-min intervals over four cycles. When stretched skin is anchored to a fixed point by suspension sutures, the elastic fibers do not revert to their original state. Intraoperative tissue expansion can also be performed by closing the wound using the rule of halves.<sup>5</sup> Each suture progressively reduces the tension across the wound as the surgeon takes advantage of tissue creep. Tissue stretching affects the skin's microcirculation with a combination of narrowing of the lumina of blood vessels and shearing fractures.<sup>7,8</sup> This tension also may result in venous congestion with subsequent compromise of healing. Highly

vascularized regions are better able to withstand tension than poorly-perfused ones that may undergo necrosis. "Stretch-back" describes the subsequent spreading of scars for wounds closed under tension. Most of the spreading of the scar occurs during the first 8 postoperative weeks and is completed at 12 weeks. On the scalp, upper back, and deltoid region, the benefits of excision for aesthetic indications is compromised by scar spreading. It is important to be aware of the capacity for stretch-back before planning the surgery.

## Head and neck soft tissue anatomy

Significant variations in the skin of the head and neck and the relationship to underlying adipose tissue, cartilage, and bone occur within dramatically short distances of a few centimeters of the scalp, eyelids, lips, and chin (Fig. 1.3). The scalp is divided into five layers that are identified by

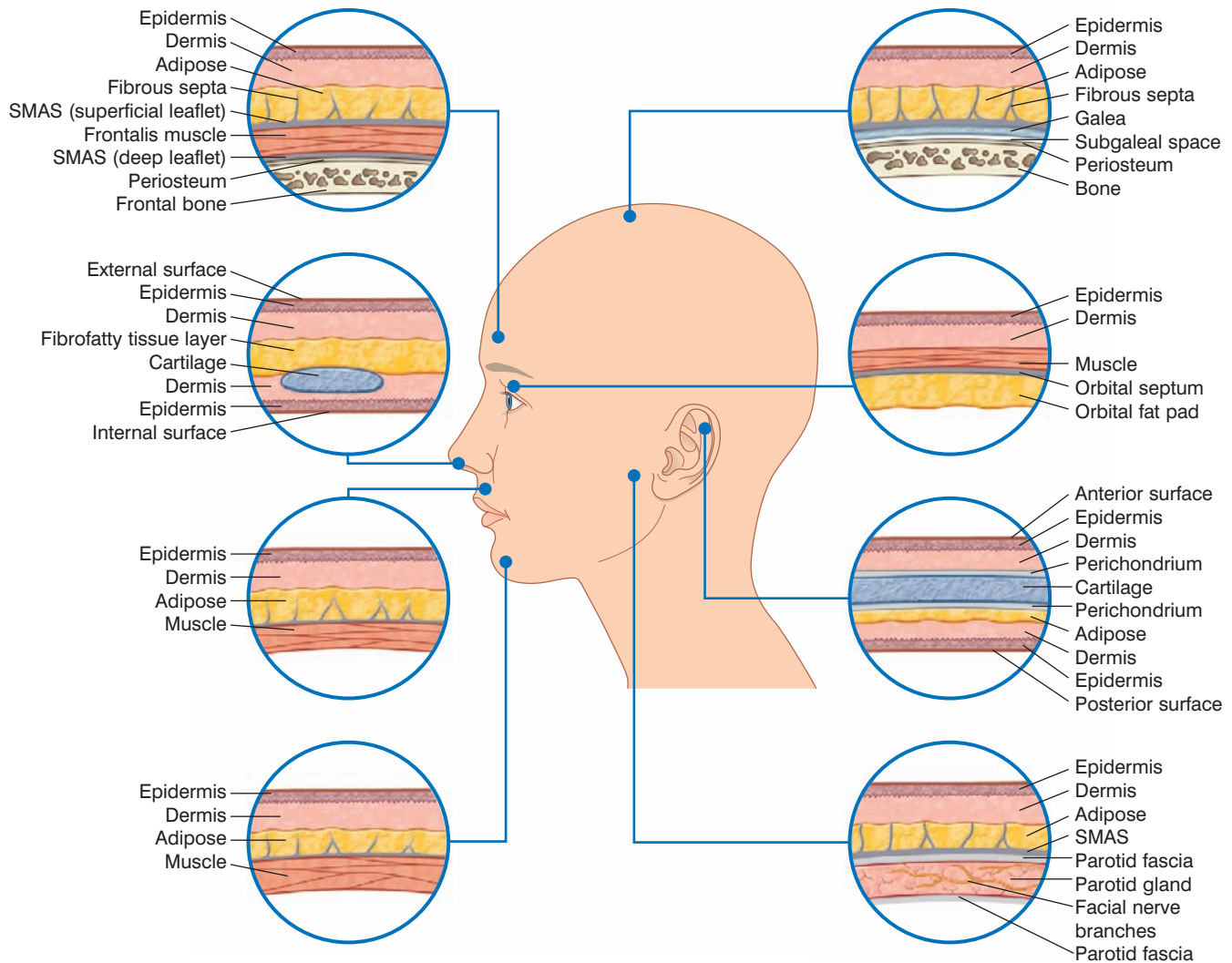


FIGURE 1.3 Facial skin cross-sections showing variations of the skin and its relationship to deeper layers. (Modified with permission from Wheeland RG. *Cutaneous surgery*. Philadelphia: WB Saunders; 1994:51.)

the mnemonic “SCALP”, which describes the layers from superficial to deep as S, skin; C, subcutaneous tissue; A, aponeurosis (galea); L, loose connective tissue; and P, periosteum.<sup>9</sup> The cutaneous nerves and vessels of the scalp are in the dermal skin layer with larger vessels in the subcutaneous fat. There are virtually no vessels in the subgaleal space of loose connective tissue, which makes it the ideal plane to undermine scalp tissue. However, scattered emissary vessels that are transmitted through the skull are occasionally encountered and must be planned for during scalp surgery. All nerves and vessels of the scalp originate below the level of the brow as it is extended circumferentially around the scalp. No motor nerves are found on the scalp.

The fibrous bands connecting the dermis to the aponeurosis or fascia on the face and the body are accentuated in the scalp. During surgery in the subcutaneous fat of the scalp, there is significant resistance to lateral movement and substantial undermining has to be performed to close even small wounds.<sup>10</sup> The rich vascular supply of the scalp means that undermining in the subcutaneous tissue is routinely associated with heavy bleeding. To mitigate this problem, most dermatologic surgeons carry their incision through the galea. Because the galea is so inelastic, the underside of it may be scored (galeatomy) to enhance its ability to stretch over the periosteum to close the defect. The galea is an aponeurosis connecting the frontalis muscle of the forehead with the occipitalis muscle of the posterior scalp, which is why the area is referred to as one structure, the occipitofrontalis muscle. The galea extends from the superior occipital line to approximately 2 cm below the frontal hairline on the forehead where it interdigitates with the SMAS.

The skin of the eyelids, which is the thinnest on the entire body, has a rich vascular supply and no subcutaneous fat. The skin lies directly on the muscle, with a minimal or no fatty layer. Caution is needed when making incisions because even an incision limited to a few millimeters is relatively deep here. Without the protective buffer of fat that exists in other areas, there is the possibility of the novice incising too deeply and inadvertently injuring the orbital septum and entering the highly vascular retro-orbital fat.

As in the periorbital area, the voluntary muscles of the perioral and chin area insert directly into the skin, which is why dynamic (animation) wrinkles in these areas are so prominent. The muscles are thick and large, especially on the chin, and undermining is often difficult and associated with increased bleeding. Blunt dissection on the chin is often hampered by the presence of the diagonally and vertically inserting muscular fibers and minimal subcutaneous space to dissect within. By contrast, the skin of the lateral cheeks has no direct muscle insertions and blunt undermining in subcutaneous tissue can be carried out with minimal effort.

In the postauricular area, anterior to the mastoid area, the fatty layer is often very thin. The most posterior aspect of the parotid gland is in this area and protects the facial nerve. The gland is grayish-tan in color and a bit denser in consistency than adipose tissue and must be avoided.

## Cosmetic units of the face

Boundaries or junctions of anatomic units on the face including the nasolabial fold, the nasofacial sulcus, the mentolabial crease, and the preauricular sulcus form some of the contour lines of the face. Other examples are eyelid margins, philtral columns, nasal contours, the vermilion border, and eyebrows. These junction lines divide the face into cosmetic units (Figs 1.4–1.9).<sup>11,12</sup> It is important that these boundaries are respected as much as possible during surgery. Other facial contour lines are wrinkles, which are best delineated in the seated and animated patient. Age and sun exposure can accentuate the wrinkles that appear along the course of the relaxed skin tension lines. These lines generally occur perpendicular to the long axis of the underlying musculature.

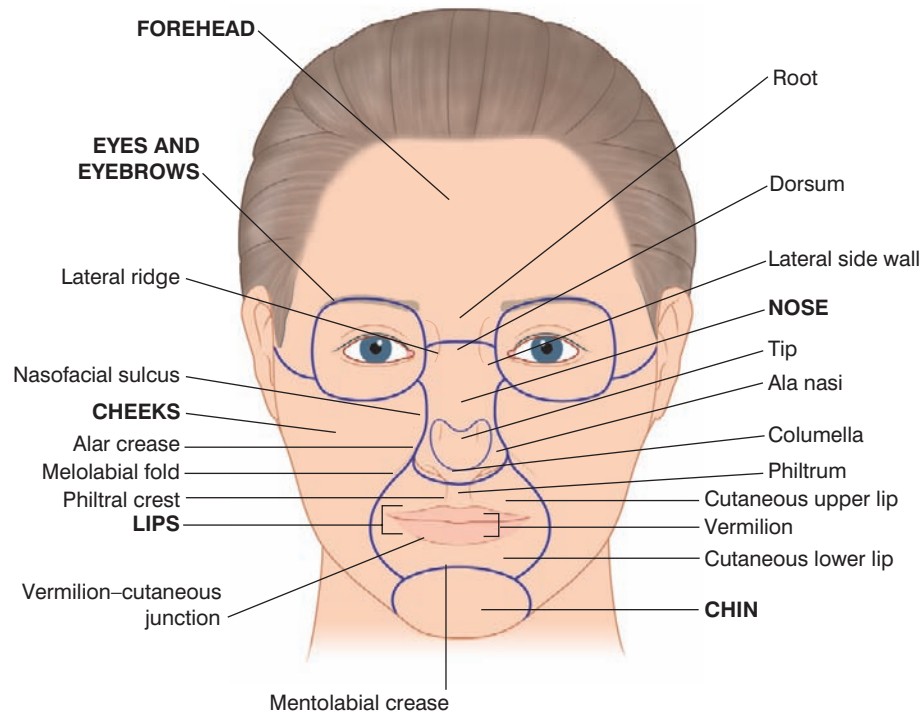
The major aesthetic units of the face (the forehead, nose, eyes, lips, cheeks, and chin) (Figs 1.4–1.9) are subdivided into units whose skin surface attributes are consistent within the unit. Surface characteristics such as pigmentation, texture, hair quality, pore size, sebaceous quality, and response to blush stimuli are similar within a single unit. Elasticity and mobility of the skin may vary within a unit. The boundaries of these cosmetic units may provide good places to electively place incisions. For instance, the junction of the nose and medial cheek (the nasofacial sulcus) provides a natural line of definition along which an incision may be camouflaged. These cosmetic units also reflect the surface anatomy with differences in the three-dimensional contour providing demarcation of the units.<sup>13</sup> Terminology evolves to meet clinical demands, thus the lip region is now classified in 15 anatomic zones to better direct placement of injectable fillers (Fig. 1.9B).<sup>14</sup>

Volume changes in the skin and soft tissue contribute to age- and disease-related facial reshaping. Gravity determines the direction of facial tissue festooning but is not the cause of the tissue deflation. The soft tissue is draped over the craniofacial support system; therefore, bone reabsorption due to aging is the major contributor to the appearance of the aging face. As the aging mandible becomes smaller, the cosmetic unit of the cheek and chin becomes prominent, thus the perioral area has the appearance of a puppet – Marionette lines. With thyroid associated orbitopathy, the dermal and subdermal tissues are infiltrated, the eyebrow region becomes thickened and coarse. There is a change in the shape of the brow with a lateral flare or “C” shape and a rounded bulge of tissue between the lateral brow and the temporal fossa. Surgical rehabilitation of these patients requires eyebrow remodeling with sculpting of the eyebrow fat.<sup>15</sup>

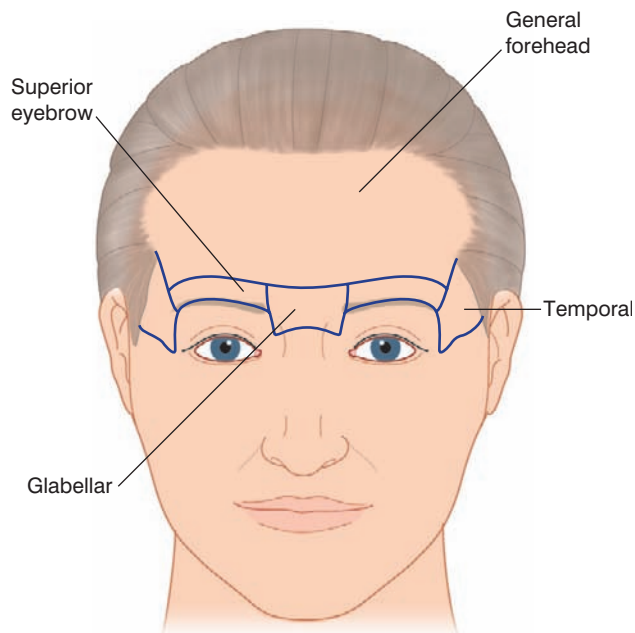
## Skin tension lines

The inherent properties of the dermal collagen and elastic tissue of skin in various regions combined with the tension intermittently exerted on it by the underlying muscles results in linear wrinkles (Figs 1.10–1.12). Over the years, stretching of the collagen in the direction of the pull of the muscles produces wrinkles. The elastic tissue is able to

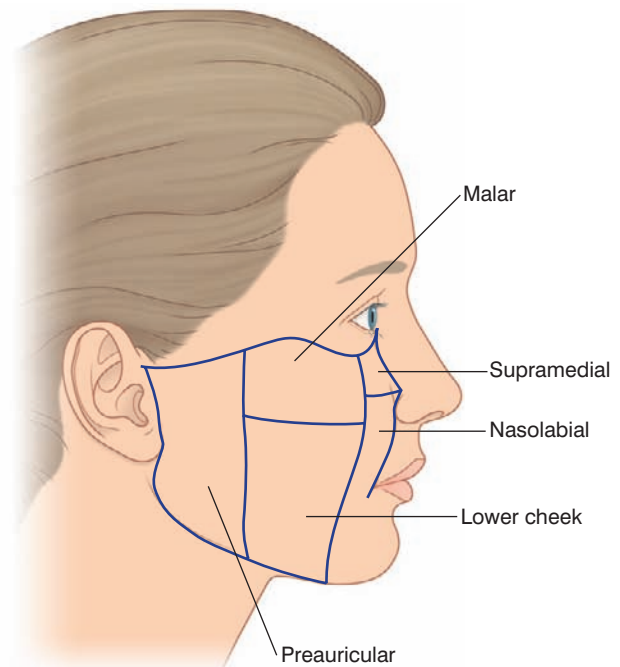




**FIGURE 1.4** The boundaries of the six cosmetic units of the face (forehead, cheeks, eyes, nose, lips, and chin) are defined by the contour lines of the nose, lips, and chin. (After Robinson JK. Basic cutaneous surgery concepts. In: Robinson JK, Arndt KA, LeBoit PE, Wintroub BU, eds. *Atlas of cutaneous surgery*. Philadelphia: Saunders; 1996:1–4, with permission from Saunders.)



**FIGURE 1.5** Four components of the forehead. (After Robinson JK. Basic cutaneous surgery concepts. In: Robinson JK, Arndt KA, LeBoit PE, Wintroub BU, eds. *Atlas of cutaneous surgery*. Philadelphia: Saunders; 1996:1–4, with permission from Saunders.)



**FIGURE 1.6** Five components of the cheek. (After Robinson JK. Basic cutaneous surgery concepts. In: Robinson JK, Arndt KA, LeBoit PE, Wintroub BU, eds. *Atlas of cutaneous surgery*. Philadelphia: Saunders; 1996:1–4, with permission from Saunders.)

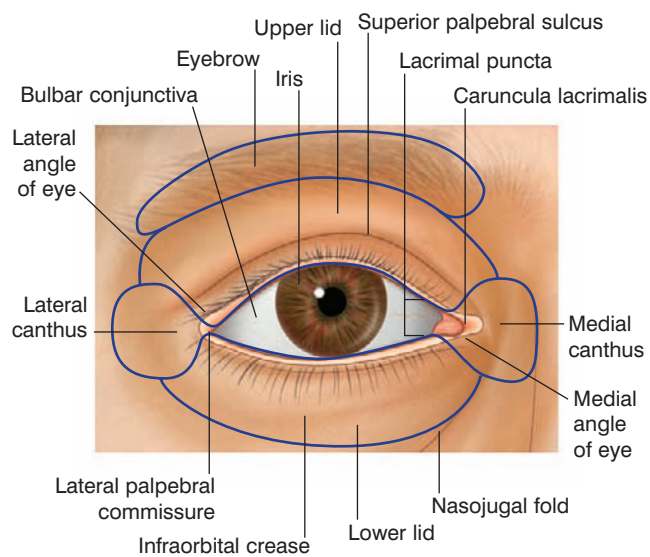


FIGURE 1.7 Topographic landmarks of the periorbital region. (After Robinson JK. Basic cutaneous surgery concepts. In: Robinson JK, Arndt KA, LeBoit PE, Wintroub BU, eds. *Atlas of cutaneous surgery*. Philadelphia: Saunders; 1996:1–4, with permission from Saunders.)

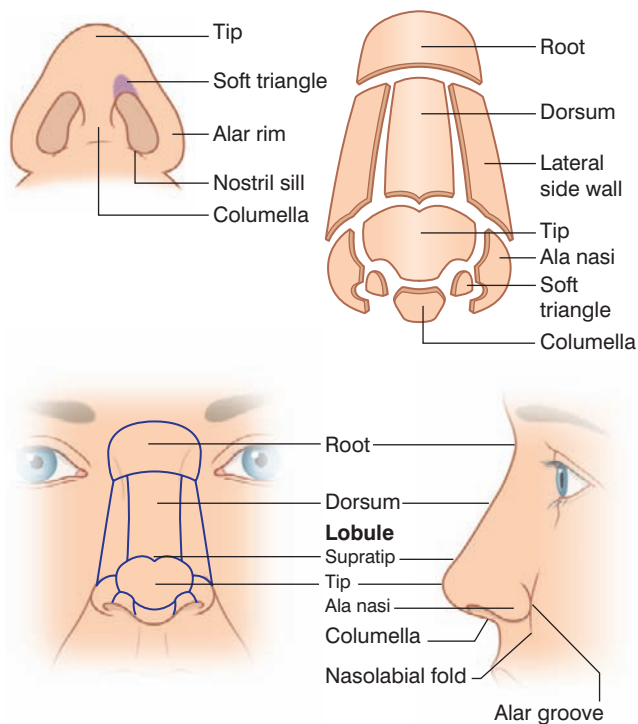
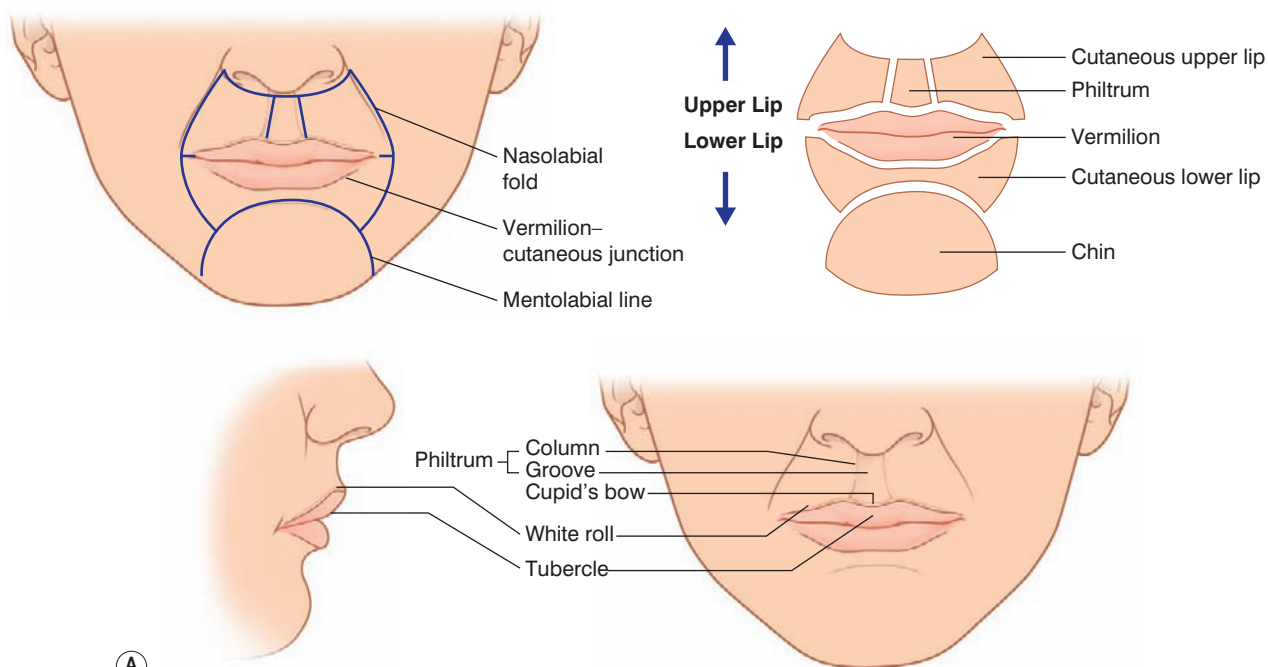
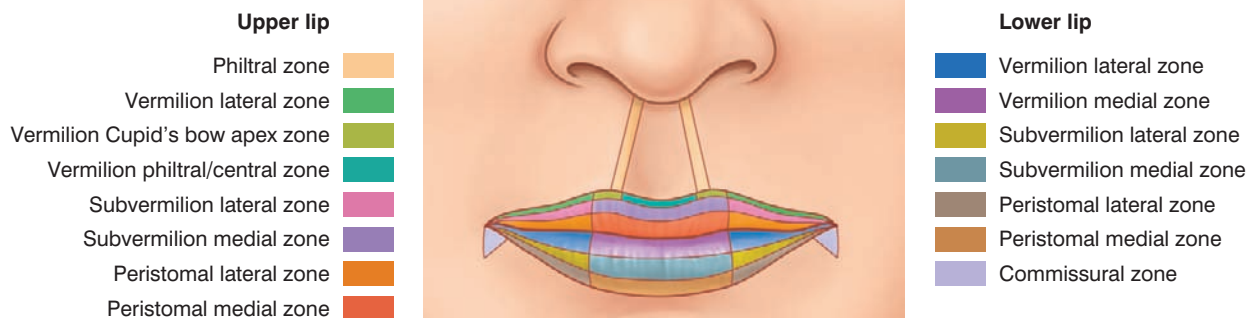


FIGURE 1.8 Topographic landmarks of the nose.



(A)



(B)

FIGURE 1.9 (A) Topographic landmarks of the lips: anterior and lateral views. (B) Subdivision into 15 units for lip augmentation.

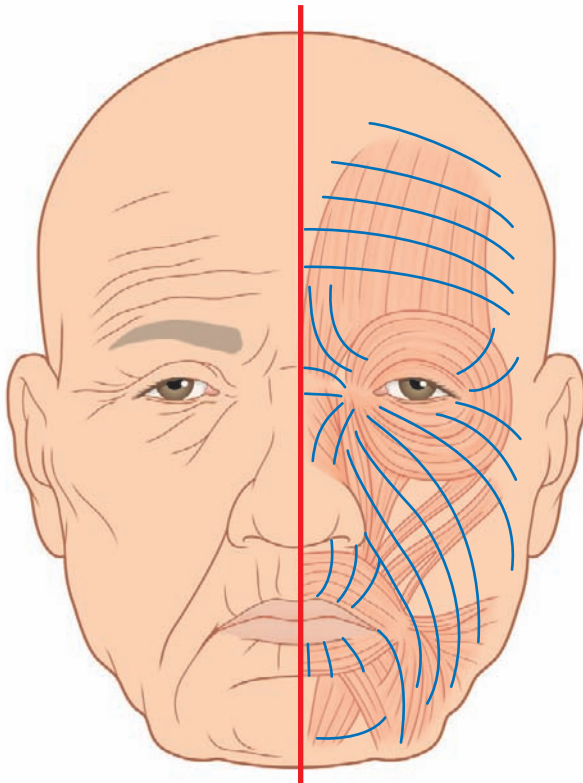


FIGURE 1.10 Facial skin tension lines and the facial muscles. Over a period of years the pulling of the muscles of facial expression on the skin and loss of elasticity result in the redundant skin forming wrinkles. (After Salasche SJ, Bernstein G, Senkarik M. *Surgical anatomy of the skin*. Norwalk, CT: Appleton, with permission from The McGraw Hill Companies Inc ©.)

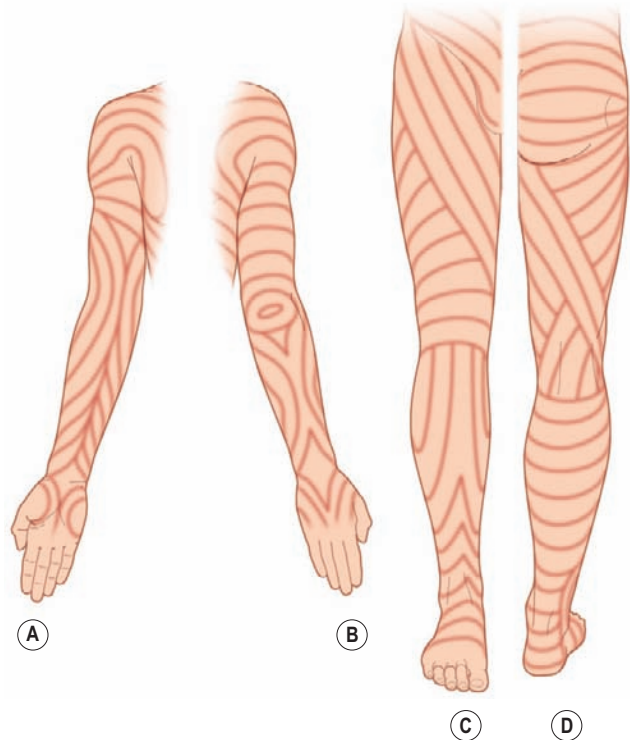


FIGURE 1.12 Relaxed skin tension lines of the extremities. (A) Upper arm; (B) lower arm; (C) anterior leg; (D) posterior leg. (After Robinson JK. Basic cutaneous surgery concepts. In: Robinson JK, Arndt KA, LeBoit PE, Wintroub BU, eds. *Atlas of cutaneous surgery*. Philadelphia: Saunders; 1996:1–4, with permission from Saunders.)

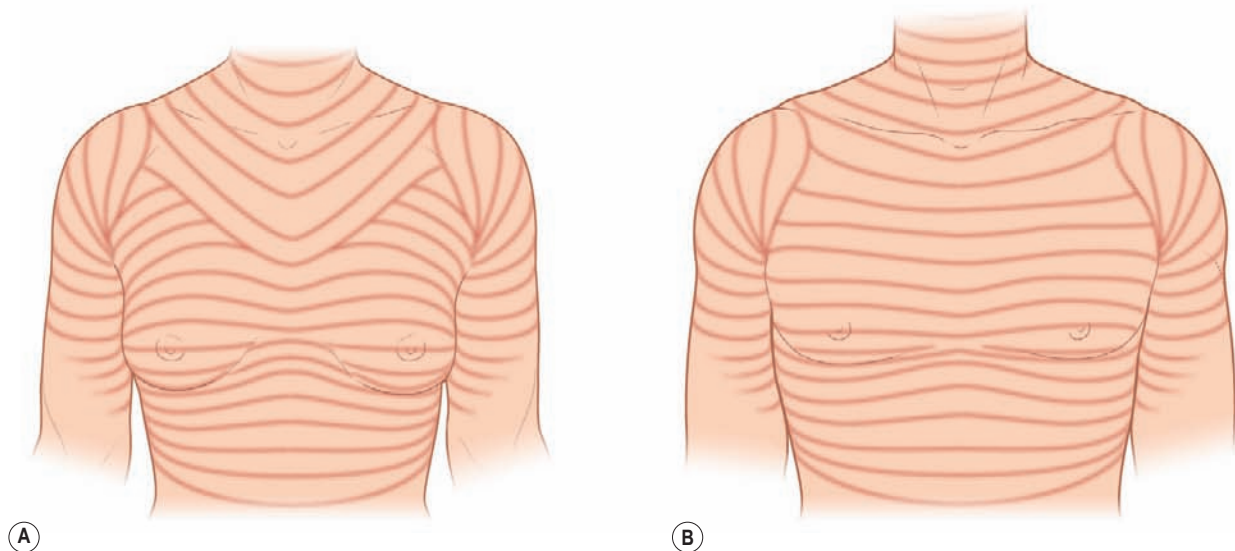


FIGURE 1.11 Relaxed skin tension lines of the body in (A) a woman and (B) a man. (After Robinson JK. Basic cutaneous surgery concepts. In: Robinson JK, Arndt KA, LeBoit PE, Wintroub BU, eds. *Atlas of cutaneous surgery*. Philadelphia: Saunders; 1996:1–4, with permission from Saunders.)

maintain the smooth shape of the skin; however, as the skin loses its elasticity with age, the redundant skin ripples into wrinkles and folds. The linear wrinkles on the face form along the attachments of the fibers of the SMAS. When fibrous attachments of the skin to the underlying muscle do not exist, gravitational forces pull the skin into baggy areas, such as: infraorbital festooning, medial cheek jowling, and “turkey gobbler” neck deformity.

While areas of sagging skin are not produced solely by fat deposits, fat deposits do play a role in the contours of the face. The face consists of individual fat compartments that gain and lose fat at different rates. Malar fat is composed of three separate fat compartments: medial, middle, and lateral temporal cheek fat.<sup>16</sup> The chin or mental fat compartment is well demarcated from the adjacent compartments of the submental area and the jowl by retaining ligaments.<sup>17</sup> The ligaments vary from being well-developed to absent.

## Facial topography and relation to bony structures of the face

The surface anatomy of the face is best appreciated by referring to the bony landmarks of the frontal, maxillary, zygomatic, and mandibular bones. Each of these bones has distinctive features that contribute to the surface landmarks of the face – the orbital rims, zygomatic arch, the mastoid process, and the mentum.

The zygomatic arch is the most prominent bone of the lateral cheek. The posterior aspect of the arch helps to define the superior pole of the parotid gland, the superficial temporal artery, and some branches of the facial nerve. The mastoid process is the most inferior portion of the temporal bone and is easily palpated as a rounded projection at the inferior aspect of the postauricular sulcus. It is the landmark for identification of the emergence of the facial nerve trunk. In the adult, the mastoid process protects the facial nerve as it exits the skull through the stylomastoid foramen. The mastoid process is not fully developed until puberty, during which time the facial nerve is not fully protected. The mental protuberance of the mandible forms the prominence of the chin. The body of the mandible supports the teeth and presents a sharp inferior margin of the lower face.

The portion of the frontal bone forming the forehead has rounded projections (frontal eminences). The superciliary arches deep to the eyebrows are prominent ridges with a small elevation between the two arches (the glabella). The nasion is formed by the articulation of the paired nasal bones with the frontal bone (see Fig. 1.14).

The three important foramina in the facial bones can be identified from the surface (see Box 1.1). The supraorbital, infraorbital, and mental foramina are found along a vertical line extending from the supraorbital foramen or notch and passing through the center of the pupil (Fig. 1.13). The supraorbital foramen is 2.5 cm or approximately one thumb-breadth from the midline of the nasal root.<sup>12</sup> It can be palpated immediately above the orbit as a notch on the

### Box 1.1 Optimizing facial surgery

- Preserve the cosmetic units of the face. Remove additional tissue to place incisions at the junction of cosmetic units; use suspension sutures to fix advancing tissue to underlying support to prevent distortion of the free margins of the lip and eyelid.
- Place incisions into relaxed skin tension lines. With the patient seated, observe the formation of lines with animation of the face (e.g., grimace, frown, smile, pucker).
- Place suspension sutures into deep supporting structures: the mental crease, nasolabial fold at the junction with the alae, the zygomatic arch, the orbital rim.
- Mobilize tissue. Plan tissue movement to access the lax tissue of the temple, nasolabial fold, paranasal cheek, supraorbital and infraorbital lids, glabella, neck; use cycles of intraoperative loading with skin hooks on the skin of the wound edges to produce stress relaxation; temporary retention sutures place constant force on the wound edges.
- Reduce the wound size. Undermine tissue widely in a tissue plane that results in the least amount of bleeding and plicate the SMAS.

underside of the orbital rim. From this notch the supraorbital artery, vein, and nerve emerge from the skull.

The infraorbital vessels and nerve pass through the infraorbital foramen, which is found in the maxillary bone below the infraorbital rim. In non-obese people, it can usually be palpated as a small opening 1 cm below the infraorbital rim on the backward slope of the maxilla and superolateral to the nasal ala. While the mental foramen is not usually palpable, it is typically present at the mid-portion of the mandible along the same vertical line from the supraorbital foramen (Fig. 1.13). With age, there is a reduction in the height of the mandible; the mental foramen may therefore assume a more superior location. In patients with dentures, the position of the foramen is best located by measuring about 1 cm from the inferior margin of the mandible superiorly along the midpupillary line.

## Anthropometric landmarks

A series of measures and angles form the points of reference for aesthetic planes, which attempt to codify the ideal parameters of beauty and proportion of the face. The ancient Greeks started this codification and the works from antiquity became available in the Renaissance. Leonardo da Vinci appears to have created the earliest known diagram of the facial circle (c. 1490–1492). In this circle of the profile of the face, the trichion (hairline), pronasale (nasal tip), and pogonion (anterior projection of the chin) fall along an arc (Fig. 1.14).<sup>18</sup> A line from the tragon of the ear to the pronasale forms the radius of the arc. Pleasing facial proportions divide the face into relatively equal thirds. The upper face is measured from the trichion (the anterior hairline) to the glabella (which delineates the most prominent projection of the forehead at the eyebrows). The



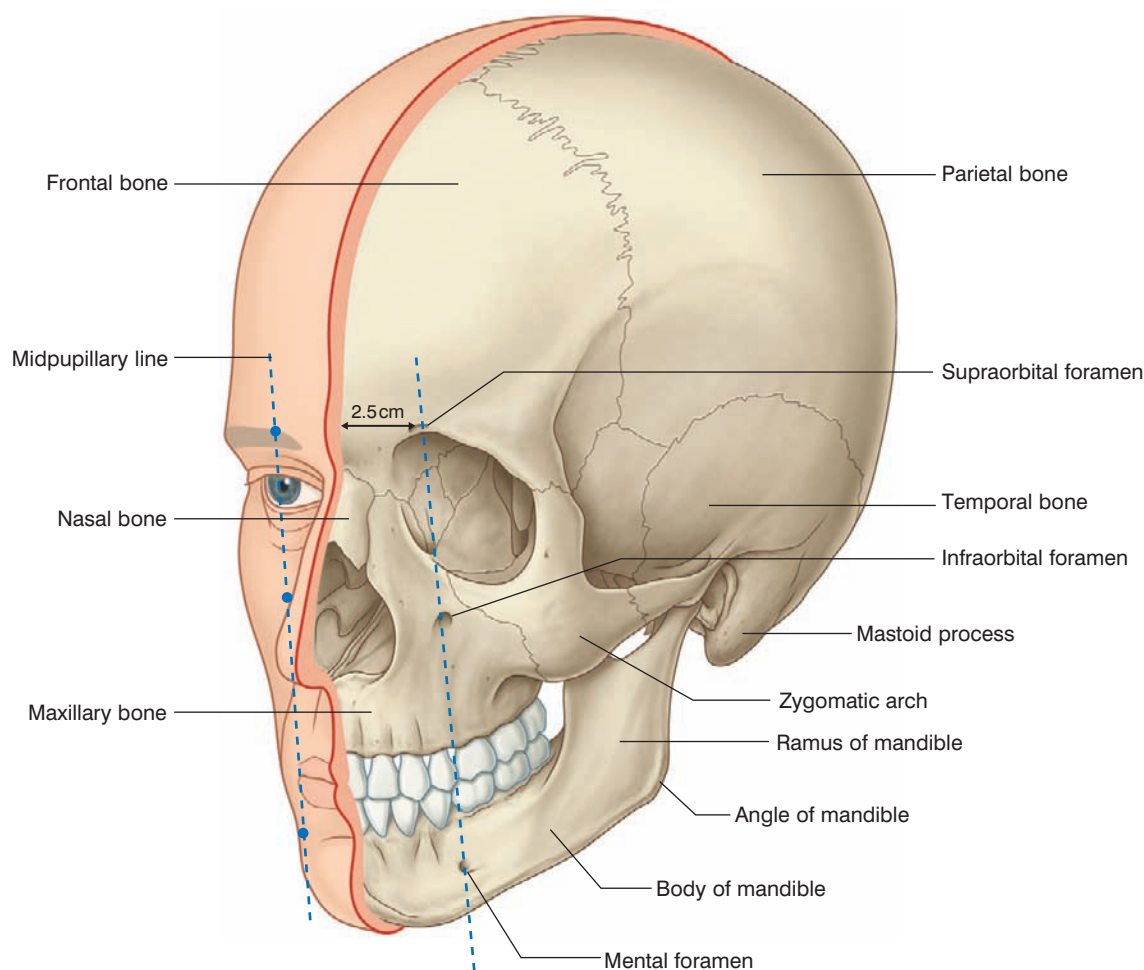


FIGURE 1.13 A vertical line approximates the location of the supraorbital, infraorbital, and mental foramina 2.5 cm from the midline.

middle-third of the face extends from the eyes and nose at the glabella to the subnasale (the inferior aspect of the nose at the junction of the columella and the cutaneous upper lip). The lower-third extends from the subnasale to the menton (the lowest point on the chin contour of the mandible).<sup>19</sup>

The face divides vertically into fifths, with each segment being equal to the width of the eye measured from the medial to lateral contours. The width of the eye equals the distance between the eyes (inner canthal distance); the distance from the lateral canthus to the outer rim of the helix of the ear in a full frontal view; and the width of the nose from ala to ala (Fig. 1.15). The central facial dimensions are further related by the interpupillary distance (solid line A), being equal to the vertical distance between the medial canthi and the most inferior point of the vermilion of the upper lip (the stomion superius; solid line B).

The ideal brow is defined by two lines: one drawn from the lateral alar rim to the outer canthus of the eye which continues on to the lateral tail of the brow. The other line, drawn obliquely from the lateral alar rim through the medial canthus to the brow, defines the highest point of

the brow arch. The lips ideally extend from the medial limbus of one eye to the medial limbus of the other. A slanted line connecting the highest point of the upper lip at Cupid's bow with the most lateral aspect of the vermilion border of the upper lip should parallel a line connecting the mid and highest point of the supracanthal fold of the eyelid and the lateral-most border of this fold. These landmarks can be helpful to achieve the most aesthetically pleasing results during facial reconstruction surgery.

## Anatomic landmarks of the face (Video 1.1)



### Parotid gland

Before planning a surgical procedure, the important structures that lie below the surface are localized by referring to surface landmarks. Asking patients to clench their teeth and jaw and palpating the leading edge of the muscle on the cheek identifies the masseter muscle. The muscle originates on the zygomatic arch and inserts on the ramus, angle, and body of the mandible. The parotid gland is on the posterior half of the masseter muscle and extends from the tragus to just above the angle of the mandible. The anterior border can generally be found by dropping a line down from

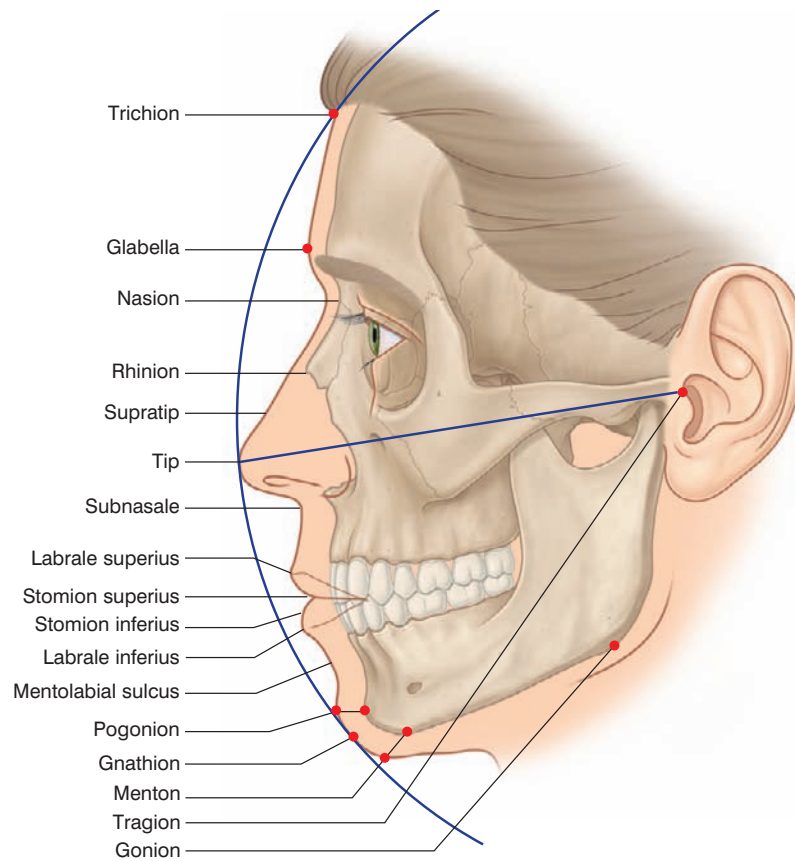


FIGURE 1.14 Anthropometric landmarks of the profile. (After Salasche SJ, Bernstein G, Senkarik M. *Surgical anatomy of the skin*. Norwalk, CT: Appleton & Lange; 1988, with permission of The McGraw Hill Companies Inc ©.)

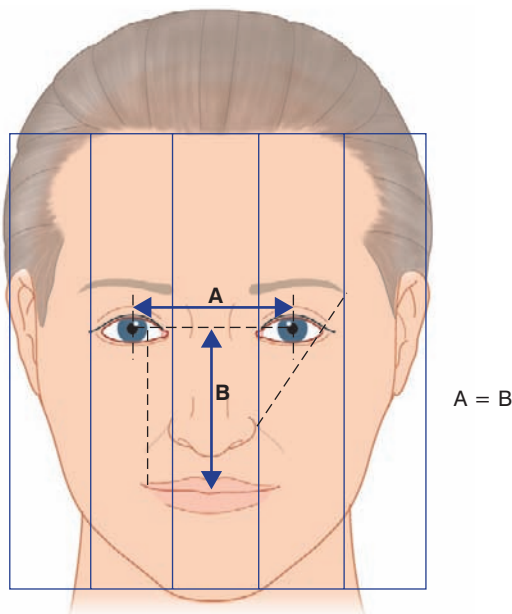
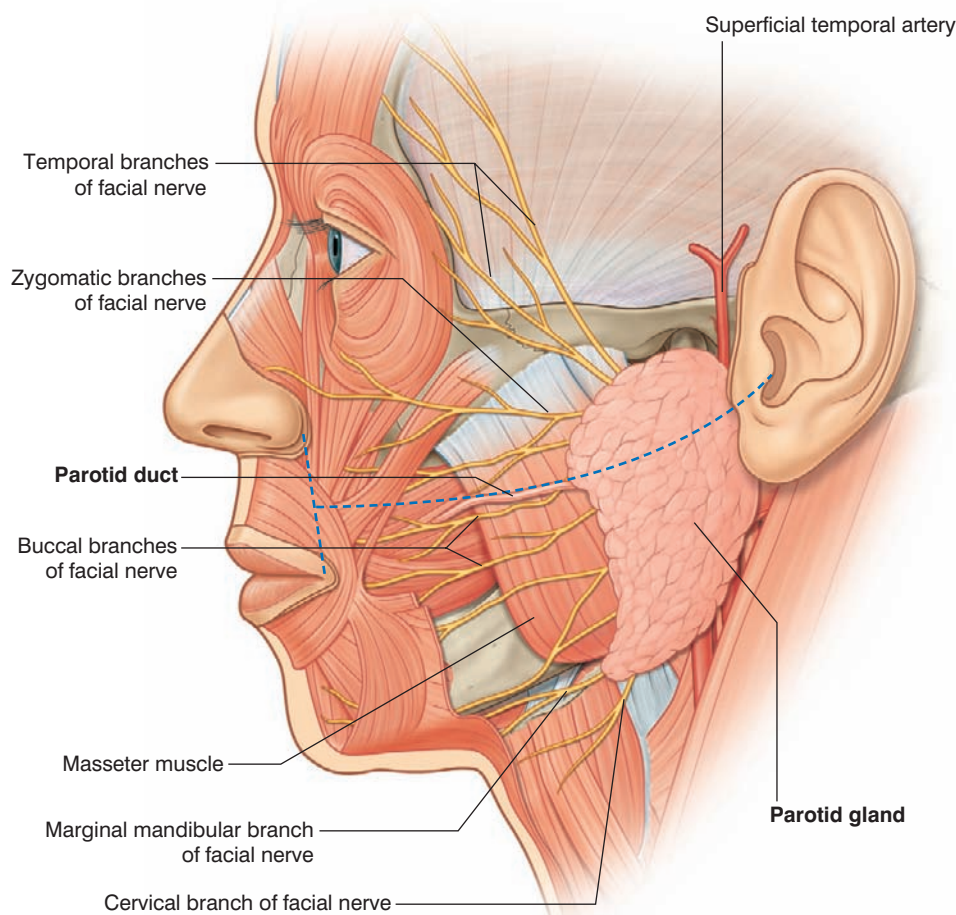


FIGURE 1.15 Central facial relationships. (After Salasche SJ, Bernstein G, Senkarik M. *Surgical anatomy of the skin*. Norwalk, CT: Appleton & Lange; 1988, with permission of The McGraw Hill Companies Inc ©.)

the lateral canthus. It has a somewhat triangular shape with the parotid duct (Stensen's duct) emerging from the anterior border of the parotid. The parotid duct drains the secretions of the parotid gland into the interior of the mouth as it enters the mouth opposite to the second molar tooth. The duct courses along the middle third of a line drawn from the notch of the ear above the tragus to a point midway between the oral commissure and the alar rim (Fig. 1.16). This structure can be palpated as it runs across the masseter muscle when the teeth are clenched. At the anterior border of the masseter muscle, the duct makes a sharp right angle and passes through the buccinator muscle to enter the buccal mucosa at the position of the second upper molar. Cutting into the parotid gland creates a draining sinus that often heals spontaneously in a few days, but cutting the parotid duct often produces a chronic draining sinus that requires a procedure to repair it.

The facial nerve is associated with the parotid gland. Although the parotid gland protects the fibers of the facial nerve posteriorly, the branches are closer to the surface at the anterior margin of the parotid gland. The branches of the facial nerve exit the superior, anterior, and inferior poles of the parotid gland from its deep aspect and generally lie on the deep fascia of the masseter muscle (Fig.



**FIGURE 1.16** Branches of the facial nerve exit the anterior, superior, and inferior poles of the parotid gland. The point where the parotid duct crosses the anterior border of the masseter muscle is plotted along a line connecting the tragus to the middle of the upper lip, the tragolabial line. (After Robinson JK. Basic cutaneous surgery concepts. In: Robinson JK, Arndt KA, LeBoit PE, Wintroub BU, eds. *Atlas of cutaneous surgery*. Philadelphia: Saunders; 1996:1–4, with permission from Saunders.)

1.16). Although relatively deep in this area, the nerve branches are potentially exposed to injury during surgical procedures.

Another structure that can be located by its relationship to the parotid gland is the superficial temporal artery, which traverses the posteroinferior aspect of the parotid gland from infralobular to pretragal and enters the subcutaneous fat at the superior pole of the parotid gland at the zygomatic arch. The pulsation of the artery can easily be palpated pretragally and as it crosses the zygomatic arch and continues into the temple (Figs 1.17, 1.18).

### Temporal fossa

The zygomatic arch, the tail of the eyebrow, the coronal suture line, and the temporal hairline delineate the boundaries of the temple. It lies superior to the lateral cheek and above the parotid gland. This area is an important landmark for identification of the most superficial course of the temporal branch of the facial nerve and is therefore called a danger zone. The lateral margin of the frontalis muscle

generally extends to the lateral tip of the eyebrow along the coronal suture line. Medially and superiorly to this point the branches of the nerve are protected by their location below the muscle; however, lateral to the brow the nerve overlies the SMAS and is only protected from injury by a very thin fatty layer (Fig. 1.19).

### Facial artery

The facial artery, a branch of the external carotid artery, is palpated as it crosses the inferior mandibular rim immediately anterior to the insertion of the masseter muscle (Fig. 1.20, Box 1.2). This point is also helpful in locating the course of the mandibular branch of the facial nerve. After crossing the mandibular rim, the facial artery and vein then follow an anterosuperior course in the direction of the oral commissure (Fig. 1.21). Near the angle of the mouth, the inferior labial artery and then the superior labial artery branch off medially. The facial artery then courses along the medial cheek near the nose as the angular artery and enters the orbit immediately above the medial canthal



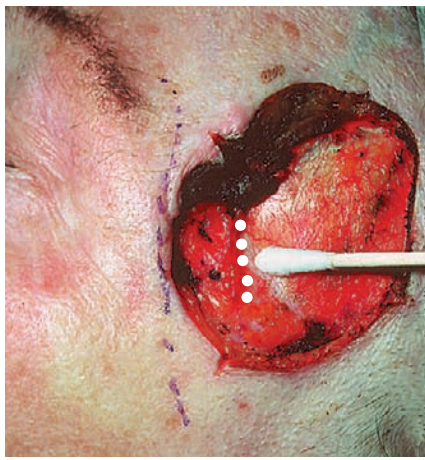

FIGURE 1.17 Relationship of the temporal artery to the temporal branch of the facial nerve. The frontal branch of the temporal artery lies to the left of the line of white dots pointed to with the cotton-tip applicator. One of the temporal branches of the facial nerve is marked on the skin with gentian violet. (After Robinson JK. Basic cutaneous surgery concepts. In: Robinson JK, Arndt KA, LeBoit PE, Wintroub BU, eds. *Atlas of cutaneous surgery*. Philadelphia: Saunders; 1996:1–4, with permission from Saunders.)

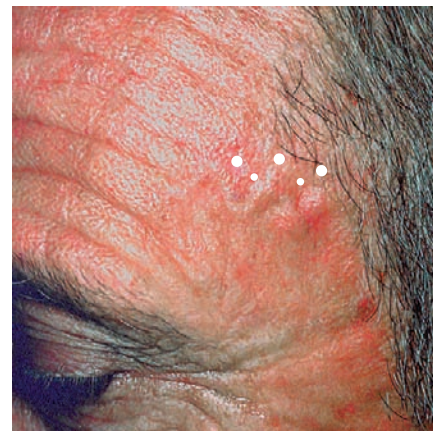

FIGURE 1.18 The tortuous engorged frontal branch of the temporal artery is visible on the surface of the skin (highlighted by white dots). (After Robinson JK. Basic cutaneous surgery concepts. In: Robinson JK, Arndt KA, LeBoit PE, Wintroub BU, eds. *Atlas of cutaneous surgery*. Philadelphia: Saunders; 1996:1–4, with permission from Saunders.)

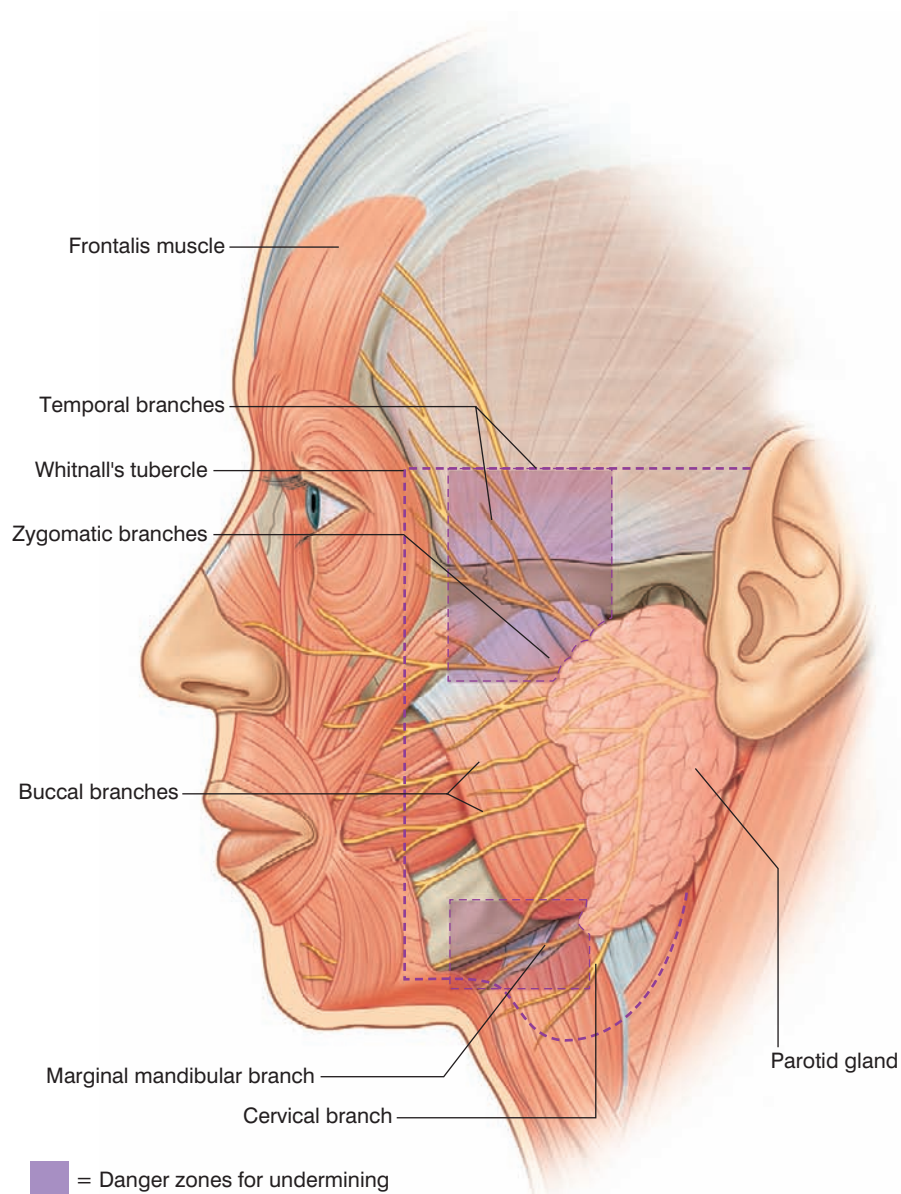
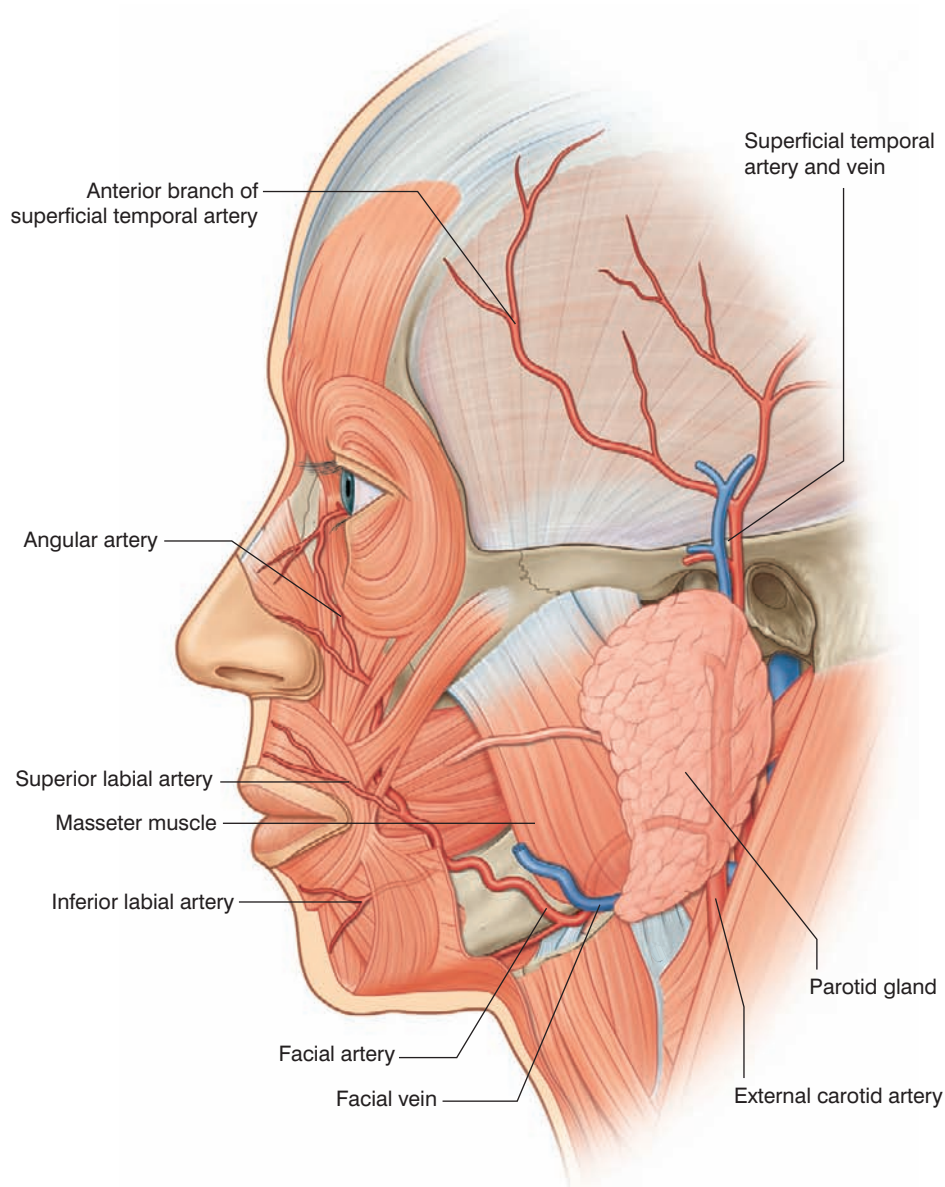


FIGURE 1.19 Branches of the facial nerve. The shaded area represents the “non-protected zone” where branches have emerged from the parotid gland. (After Robinson JK. Basic cutaneous surgery concepts. In: Robinson JK, Arndt KA, LeBoit PE, Wintroub BU, eds. *Atlas of cutaneous surgery*. Philadelphia: Saunders; 1996:1–4, with permission from Saunders.)





**FIGURE 1.20** Arterial supply of the face in relationship to the masseter muscle and parotid gland. (After Robinson JK. Basic cutaneous surgery concepts. In: Robinson JK, Arndt KA, LeBoit PE, Wintroub BU, eds. *Atlas of cutaneous surgery*. Philadelphia: Saunders; 1996:1–4, with permission from Saunders.)

tendon to anastomose with the ophthalmic artery branches (Fig. 1.22).

### *Sternocleidomastoid muscle*

The sternocleidomastoid muscle originates from the sternum and clavicle and extends in a posterior diagonal fashion to insert onto the ipsilateral mastoid process and lateral portion of the occipital ridge. The muscles work together to flex the neck and work individually to turn the neck and elevate the chin. With the head rotated away from the observer, the sternocleidomastoid muscle becomes a prominent surface landmark that divides the neck into the anterior and posterior triangles. The muscle and the mastoid process are important landmarks used to identify the spinal

accessory nerve at its most exposed location in the posterior triangle (Fig. 1.23).

### *Facial muscles*

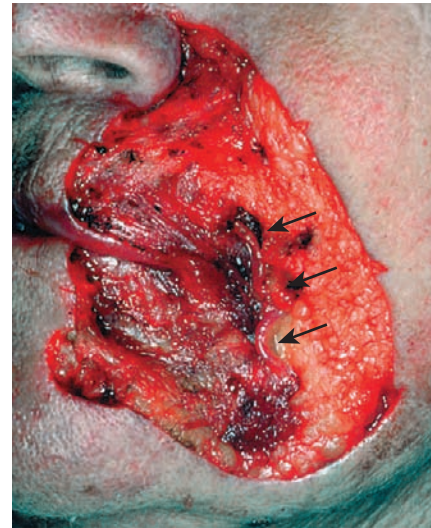
Branches of the facial nerve innervate all the muscles of facial expression (Table 1.1). These muscles originate or insert into the skin itself (Figs 1.24, 1.25). This is in contrast to the muscles of the body, which originate and insert on the bony structures that they move. The major function of the facial muscles is expression, which is important in non-verbal communication, and mouth and eyelid function. The SMAS represents a continuous layer of fascia, which encases and connects all the muscles of facial expression with overlying skin through fibrous bands. It interconnects,

### Box 1.2 Practical applications of anatomy for procedural dermatology

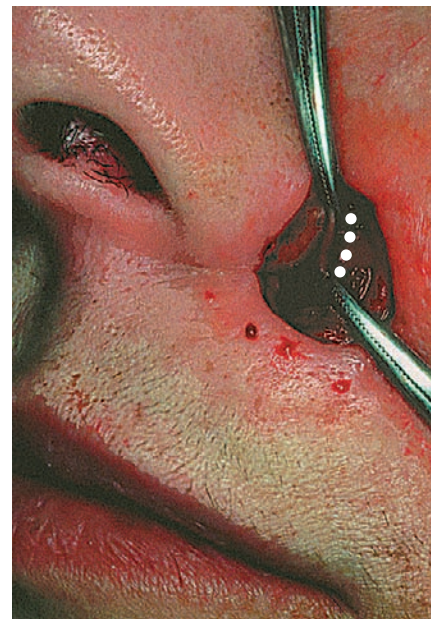
- Recognize the danger zones for arterial bleeding:
  - the frontal branch of the temporal artery at the temple
  - the facial artery as it crosses the mandibular rim
  - the angular artery as it courses near the nose.
- Recognize the danger zones for nerve transection:
  - the temporal branch of the facial nerve
  - the spinal accessory nerve in the posterior triangle of the neck
  - the marginal mandibular nerve as it courses in the neck below the mandible.
- Know where to perform nerve blocks:
  - facial nerve blocks at the supraorbital, infraorbital, and mental nerve foramina – all the foramina are located along a vertically oriented midpupillary line
  - digital blocks in the web space rather than along the digit to decrease the risk of nerve injury by compression with the volume of local anesthesia
  - ankle block – posterior tibial nerve (see [Chapter 3](#)).
- Know where to place sutures:
  - layered closures – place sutures in the muscle, SMAS, and deep subcutaneous fat, superficial subcutaneous fat, and deep dermis before the sutures that close the surface.
- Palpation of lymph nodes in the head and neck:
  - postauricular nodes drain the upper posterior aspect of the ear, and the posterior parietal, mastoid, and temporal areas of the scalp
  - parotid nodes drain the lateral cheek, anterior surface of the ear, forehead, and lateral canthal area
  - submental nodes drain the medial and lower face, medial eyelid, lateral aspects of the lip, nose, gingivae of the mouth, soft palate, anterior two-thirds of the tongue, and the palatine fossa, and because they are in the midline they have the potential to drain from either the right or left central facial region of the middle two-thirds of the lip and the chin.

integrates, and unifies the action of the facial muscles and creates facial expression. The importance of the facial muscles is obvious in the patient who has lost the function of the facial nerve because of trauma or stroke or as the temporary result of local anesthesia ([Fig. 1.26](#)). If, for example, temporal nerve injury causes permanent loss of the ipsilateral frontalis muscle, causing loss of horizontal forehead rhytides and descent of the brow on the affected side, the normal side may be temporarily treated by injection of botulinum toxin to block the function of the nerve or a brow-lift may ensue.

The muscles are categorized by regions of the face, with groups of muscles acting in concert together thanks to the SMAS, rather than as individual muscles (e.g., mouth, nose, eye, and ear). Muscles of the upper face (periorbital) act primarily in the vertical direction, whereas those of the lower face (perioral) work in both vertical and horizontal directions. The frontalis muscles of the upper face normally function as one unit that raises the eyebrows and, secondarily, the eyelids. Nerve injury here causes more of a



**FIGURE 1.21** The course of the facial artery is shown as it enters the face at the lower border of the jaw, just in front of the anterior border of the masseter muscle. It is possible to palpate the pulsation here. The diagonal path across the face lateral to the oral commissure is shown by the arrows. (After Robinson JK. Basic cutaneous surgery concepts. In: Robinson JK, Arndt KA, LeBoit PE, Wintroub BU, eds. *Atlas of cutaneous surgery*. Philadelphia: Saunders; 1996:1–4, with permission from Saunders.)

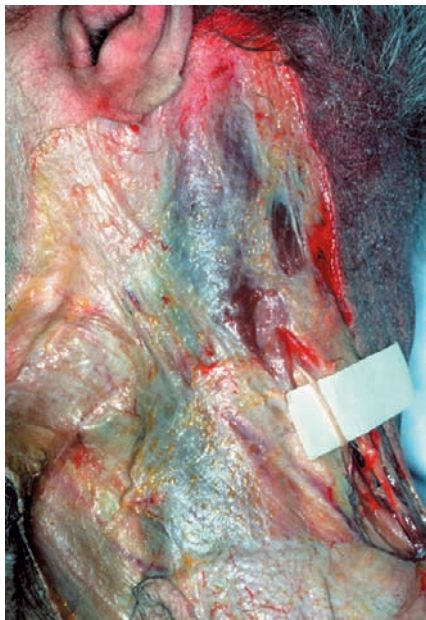


**FIGURE 1.22** The facial artery lies adjacent to the nose as the angular artery. It is to the left of the line of white dots.

cosmetic than a functional derangement, whereas injury to motor nerves of the lower face causes substantial cosmetic and functional loss as a result of mouth dysfunction.

#### Periorbital muscles

The major muscle around the eyes is the orbicularis oculi, which has an orbital and a palpebral component. The palpebral muscle is further divided into preseptal and pretarsal components. The muscle only inserts into the bone at the



**FIGURE 1.23** The spinal accessory nerve at its most exposed location. (After Robinson JK. Basic cutaneous surgery concepts. In: Robinson JK, Arndt KA, LeBoit PE, Wintroub BU, eds. *Atlas of cutaneous surgery*. Philadelphia: Saunders; 1996:1–4, with permission from Saunders.)

medial canthus. The palpebral portion, which covers the eyelid, acts to gently close the lid. Contracting the orbital portion of the muscle closes the lids more tightly and draws them medially. The orbicularis oculi muscle does not open the eyelids. The eyelid is opened by the levator palpebrae superioris, which originates within the orbit and is innervated by branches of the third cranial nerve. Thus, loss of function of the orbicularis oculi results in the levator palpebrae superioris working unopposed so the eyelids do not close. The orbicularis oculi muscle is innervated primarily by the zygomatic branch of the facial nerve, but the upper portion of the muscle is also partially innervated by the temporal branch of the facial nerve. Paralysis of these muscles by nerve loss leads to inability to fully or tightly close the lids and possibly ectropion formation (Fig. 1.27).

The bilateral corrugator supercilii muscles arise from the medial part of the superciliary ridge to insert into the skin of the brow. They draw the brow medially causing “hooding” and contribute to the formation of the deep vertical furrow of the glabella.

The procerus muscle is a solitary midline muscle that originates from the superior aspect of the nasal bones to insert into the skin overlying the root of the nose. It pulls the medial aspect of the eyebrows inferiorly and is innervated by the temporal branches of the facial nerve.

**Table 1.1** Muscles of facial expression and their functions

Region	Muscle	Actions	Innervation
Forehead and brow	Frontalis	Raises the eyebrows and accentuates the horizontal wrinkles of the forehead, assists the opening of the eyelids widely	Temporal branch of the facial nerve
	Corrugator supercilii	Produces scowling by drawing the brow medially and downward	Temporal branches of the facial nerve
	Procerus	Draws the forehead and brows inferiorly to create transverse wrinkles at the nasal root	Temporal branch of the facial nerve
Eye lid	Orbicularis oculi Levator palpebrae superioris Frontalis (see above) Procerus (see above)	Closes the eye and blinks Opens the upper eyelid	Zygomatic branch of the facial nerve
Mouth	Orbicularis oris	Draws the lips together, pulls the lips against the teeth and puckers the mouth	Buccal and marginal mandibular branches of the facial nerve
	Buccinator	Flattens the cheek against the teeth and assists with whistling	Buccal branches of the facial nerve
	Levator labii superioris alaeque nasi, levator labii superioris, zygomaticus major, zygomaticus minor	Lip elevators – produce the smile	Zygomatic branch of the facial nerve
	Levator anguli oris, risorius	Lip elevators – produce the smile	Buccal branch of the facial nerve
	Depressor anguli oris, depressor labii inferioris	Lip depressors	Marginal mandibular branch of the facial nerve
	Platysma	Lip depressors	Marginal mandibular branch of the facial nerve
	Mentalis	Lower lip elevation and protrusion	Marginal mandibular branch of the facial nerve



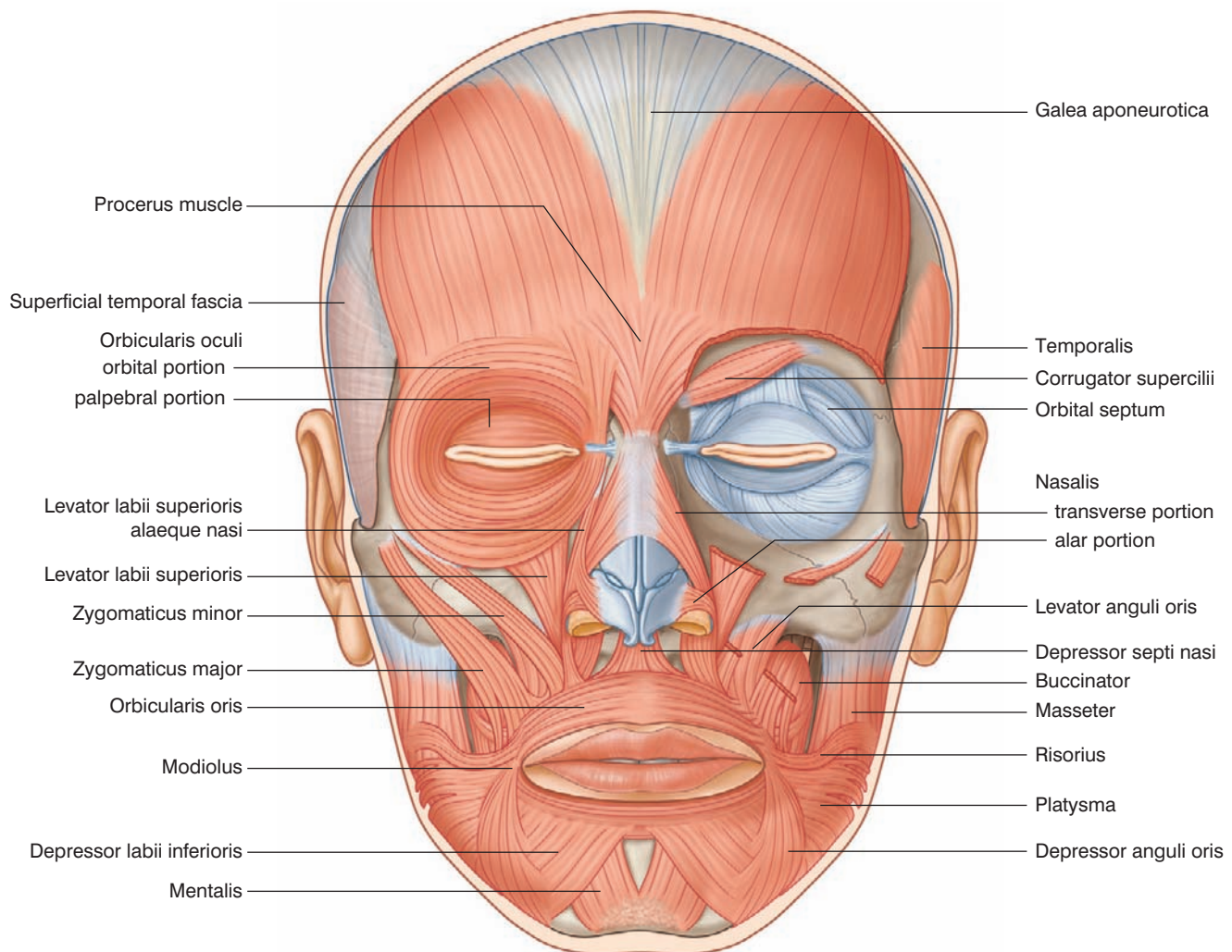


FIGURE 1.24 Frontal view of the muscles of facial expression.

### Nasal muscles

The muscles of the nose are variable in their development and have little functional importance.

### Perioral muscles

Of the muscles of the lower face, those around the mouth are the most important. These can be divided into muscles that elevate, depress, and encircle the lips. The muscles insert directly into the skin. The elevators, from medial to lateral as they insert into the lip, are the levator labii superioris, levator labii superioris alaeque nasi, zygomaticus major and minor, and levator anguli oris. These muscles originate from the upper maxilla in the infraorbital areas, insert into the upper lip and melolabial fold, and as they contract, pull the mouth up and out. The levator anguli oris, which originates in the canine fossa of the maxilla, inserts into the angles of the mouth bilaterally, and is the deepest of the elevator muscles.

The mentalis muscle is innervated by the marginal mandibular nerve. It interdigitates with the lip depressors above and platysma below, and contraction causes protrusion of the lip as well as “apple dumpling” chin

(fine pits in the skin where muscle fibers tug on overlying skin).

The depressors of the mouth from medial to lateral according to insertion in the lip include the depressor anguli oris, depressor labii inferioris and the platysma. These three muscles, which are innervated by the marginal mandibular branch of the facial nerve, pull down the lip and angle of the mouth. Injury to this vulnerable nerve results in an unopposed upward and diagonal pull on the lips causing lower lip elevation on this side, which is most prominent when smiling. At worst, this may give the appearance of a sneer. This may also be associated with some loss of function (i.e., drooling).

The orbicularis oris is the sphincter muscle responsible for pursing the lips and tight lip closure. Its muscle fibers are blended with those of many of the elevators and depressors as well as those of the platysma and risorius muscles. The deep buccinator muscle, which is also innervated by the buccal branches of the facial nerve, is the fleshy part of the mid cheek. It helps keep food from accumulating between the gums and the cheek while eating, by forcing it back into the path of the teeth.

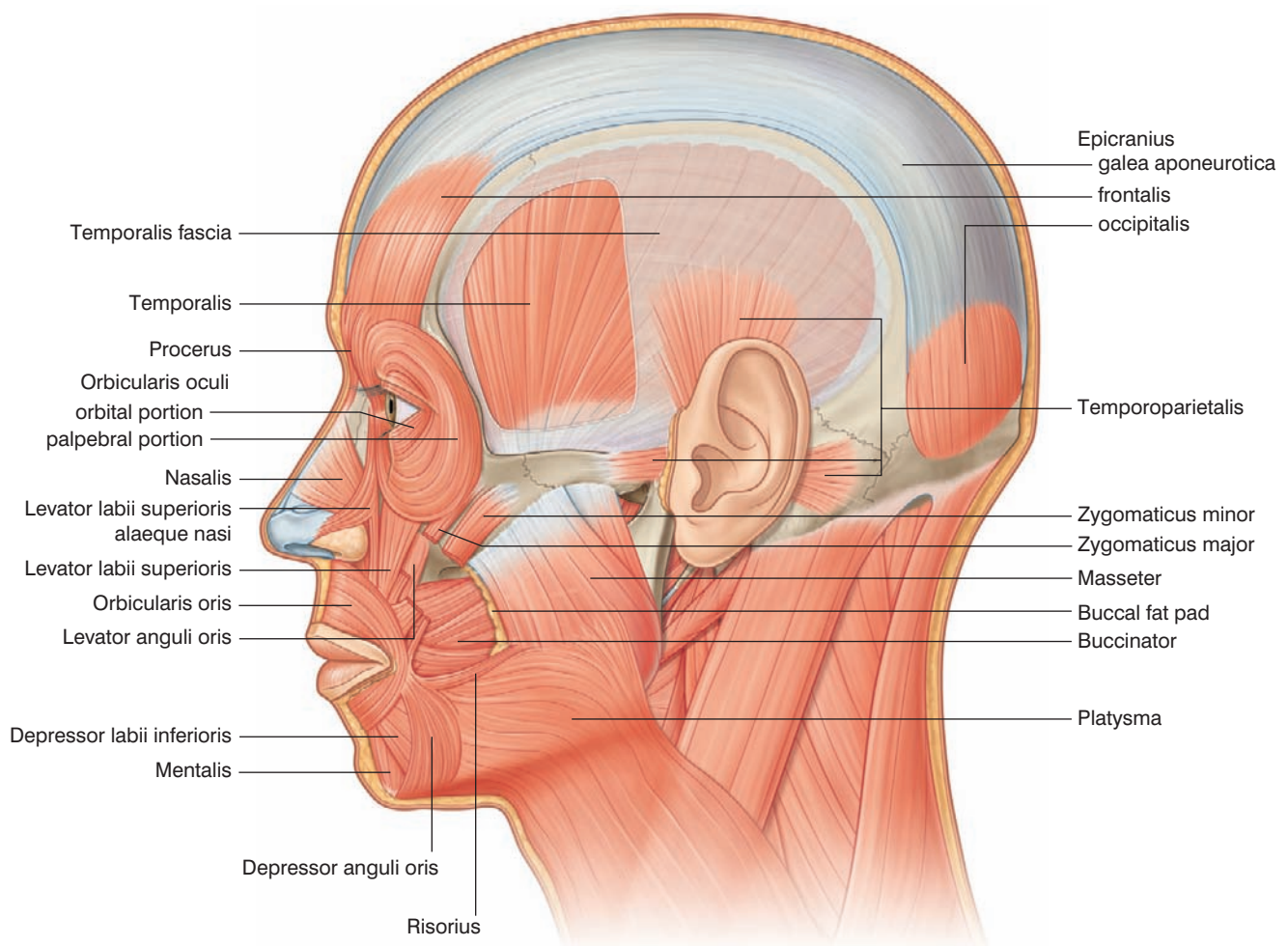


FIGURE 1.25 Lateral view of the muscles of facial expression.

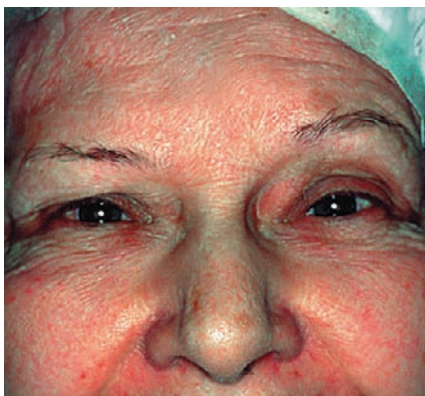


FIGURE 1.26 Loss of function of the temporal branch of the facial nerve results in a depressed brow. (After Robinson JK. Basic cutaneous surgery concepts. In: Robinson JK, Arndt KA, LeBoit PE, Wintroub BU, eds. *Atlas of cutaneous surgery*. Philadelphia: Saunders; 1996:1–4, with permission from Saunders.)

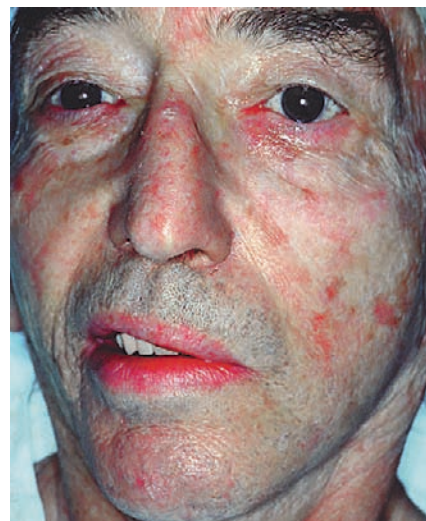

FIGURE 1.27 While providing anesthesia for the surgical procedure, the buccal and zygomatic branches of the facial nerve are temporarily paralyzed.

Lateral movement of the mouth is a function of the superficial platysma and risorius. The risorius is a paper-thin muscle that arises from the parotid fascia and passes anteriorly to insert into the skin and mucosa at the corner of the mouth. It pulls the labial commissure laterally, widening the mouth by making a smirk.

The platysma muscle is important anatomically but has little functional role. It is innervated by the cervical branches of the facial nerve. The muscle originates in the superficial cervical fascia and inserts into the orbicularis oris muscle as well as skin of the lips and chin. It is usually a broad but extremely thin muscular sheet that is responsible for tensing the skin of the neck, which gives vertical banding to the level of the clavicle in exaggerated cases. It covers and attempts to protect the marginal mandibular branch of the facial nerve as well as the facial artery and vein.

Despite the prominence of the temporalis and masseter muscles, these are not muscles of facial expression, but rather muscles of mastication.

### *Ear muscles*

The muscles of the ear are of no functional significance.

## Superficial musculoaponeurotic system

The SMAS is composed of muscle and a thin superficial layer of fascia that invests nearly all of the muscles of facial expression, especially those of the lower face, mid-face, and forehead regions. The fascial component of the SMAS arises from the superficial cervical fascial layer, envelops the platysma muscle, sweeps over the mandible, and invests the muscles of the face. Posteriorly, the fascia is tightly attached to the mastoid process of the temporal bone, the fascia over the sternocleidomastoid muscle, the superficial fascia of the parotid gland about 1–2 cm anterior to the tragus, and the zygomatic arch.

Functionally, the SMAS forms a network that binds nearly all of the muscles of facial expression together and ensures that they act in concert. The fascia provides a method of distributing the pull of the muscles evenly over the skin and acts as a deterrent to the spread of infection from the superficial to the deep areas of the face. The axial arteries are found either in the superficial aspect of the SMAS or at the SMAS–subcutaneous fat border. Thus, the sub-SMAS layer is relatively bloodless. All sensory nerves lie above the SMAS; whereas all motor muscles lie just deep to the SMAS. Dissection beneath the SMAS on the cheek is only safe when directly over the parotid gland where the nerves are found within the parenchyma of the gland. In the temporal area, dissecting above the SMAS ensures the integrity of the facial nerve. The unique features of the SMAS have resulted in significant innovations in cosmetic surgery, especially neck and face-lift surgery.<sup>20,21</sup>

## Nerve supply of the head and neck

### *Sensory innervation*

The sensory innervation of the face is derived from branches of cranial nerve V (the trigeminal nerve). It has three

branches: V1 – the ophthalmic nerve (superior branch), V2 – the maxillary nerve (middle branch), and V3 – the mandibular nerve (lower branch); these exit the skull through the supraorbital foramen, infraorbital foramen, and mental foramen, respectively. All the foramina are located along a vertically-orientated midpupillary line. Effective regional nerve block anesthesia can be achieved by blocking the nerves as they exit the foramina.

When performing surgery within the distribution of the ophthalmic and maxillary divisions of the trigeminal nerve at the orbital rim, it is possible to trigger the trigeminocardiac reflex. This causes severe bradycardia, asystole, hypotension, apnea, and even death during surgery in or near the orbit. The sensory fibers of the ophthalmic and maxillary divisions of the trigeminal nerve (afferent limb) connect with the trigeminal nucleus and the short internuncial nerve fibers of the brainstem link with the efferent limb to the motor nucleus of the vagus nerve.<sup>22</sup>

Cervical nerves derived from C2 to C4 form a plexus deep to the sternocleidomastoid muscle. The largest nerve to emerge from this plexus is the greater auricular nerve, which exits from behind the posterior border of the muscle and courses upward toward the lobule of the ear lateral to the jugular vein. It supplies the skin of the lateral neck and the skin at the angle of the jaw as well as portions of the ear. The lesser occipital nerve also emerges from behind the muscle slightly superior to the exit of the greater auricular nerve and courses upward to innervate the neck and the scalp posterior to the ear. The transverse cervical nerve emerges from behind the muscle several centimeters inferior to the great auricular nerve and crosses the muscle transversely to supply the skin of the anterior neck. This area of emergence of the great auricular, lesser occipital, and transverse nerves is Erb's point (see below, and [Fig. 1.33](#)). The importance of Erb's point is that the spinal accessory nerve (the motor nerve to the trapezius muscle) also emerges in this vicinity. Injury to the spinal accessory nerve in this relatively superficial and unprotected location will result in a loss of function of the trapezius muscle with chronic aching in the shoulders, paresthesia in the arm, dropped shoulder, and inability to actively abduct the shoulder to more than 80°.

### *Motor innervation*

The facial nerve innervates all the muscles of facial expression; therefore, it is of unique importance during surgery of the skin. In many instances, the branches of this nerve are superficial and vulnerable to trauma during surgery. When surgery is planned in these areas, patients need to be advised preoperatively of the risk of trauma to the facial nerve and the functional deficits that may result because of it.

The facial nerve has five major branches: temporal, zygomatic, buccal, marginal mandibular, and cervical. In general, the branches of the facial nerve enter the muscles that they innervate at their posterior and deep surfaces. The branches generally travel below the SMAS fascia, as opposed to sensory nerves, which run over the SMAS. If a branch is



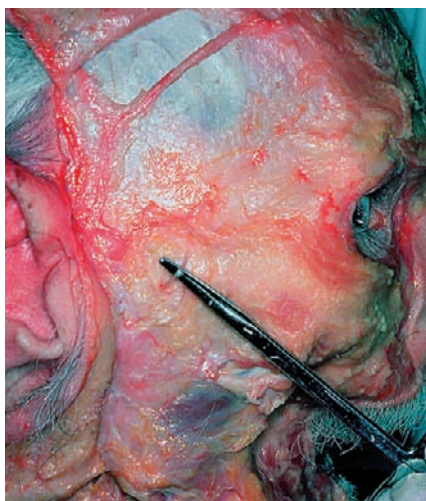


FIGURE 1.28 Cadaver prosection of the rami of the temporal branch of the facial nerve as it crosses the zygomatic arch. (After Robinson JK. Basic cutaneous surgery concepts. In: Robinson JK, Arndt KA, LeBoit PE, Wintroub BU, eds. *Atlas of cutaneous surgery*. Philadelphia: Saunders; 1996:1–4, with permission from Saunders.)

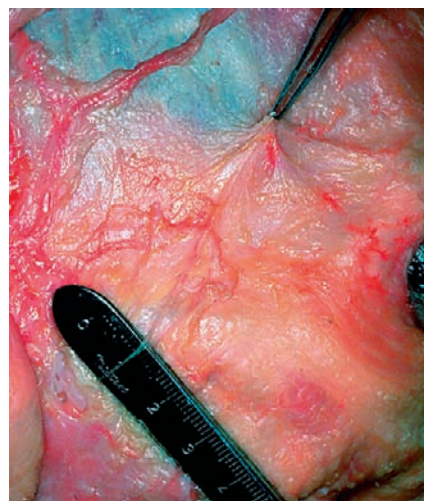


FIGURE 1.29 Cadaver prosection close-up of the same area seen in Figure 1.28. The scalpel handle is under the temporal branch of the facial nerve, which has been dissected out of the SMAS at the zygomatic arch. On the forehead, about 2 cm above the brow, the forceps pick up the nerve as it is covered with the SMAS. The nerve is clearly visible through the distance between the two surgical instruments. (After Robinson JK. Basic cutaneous surgery concepts. In: Robinson JK, Arndt KA, LeBoit PE, Wintroub BU, eds. *Atlas of cutaneous surgery*. Philadelphia: Saunders; 1996:1–4, with permission from Saunders.)

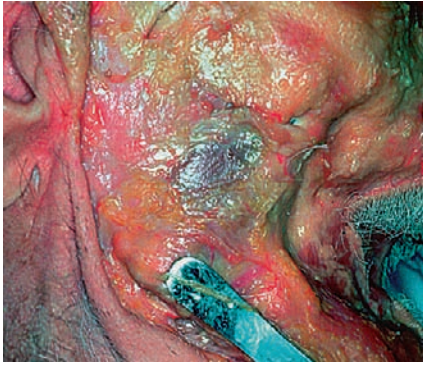
injured anterior to a vertical line drawn from the lateral canthus, the nerve can be expected to regenerate with partial function over the course of several months. Once the facial nerve branches leave the parotid gland, they are less well protected and more prone to inadvertent trauma. Hence, this region is called a “danger zone” (Fig. 1.19). The danger zone is described within the following boundaries:

- Starting at the ear, a horizontal line 1 cm above the zygoma and ending at Whitnall’s tubercle (Fig. 1.19). The lateral aspect of the brow is a useful landmark for the upper border of the danger zone
- A vertical line starting at Whitnall’s tubercle and ending at the inferior margin of the mandible
- Starting at the inferior margin of the mandible, a curved line extending 2 cm below the margin of the mandible and ending at the angle of the mandible.

The temporal branch is considered to be one of the most vulnerable branches of the facial nerve (Fig. 1.28). Drawing one line from the earlobe to the lateral tip of the highest forehead crease and a second line from the earlobe to the lateral tip of the brow and then connecting these two end-points can identify the course of this nerve. After leaving the upper pole of the parotid gland, the nerve, which may be singular or exist as multiple branches, courses upwards to innervate the frontalis muscle, upper portion of the orbicularis oculi muscle, and corrugator supercilii. The nerve is most vulnerable as it crosses the zygomatic arch and temple, where it is protected only by skin, subcutaneous fat, and a thin layer of SMAS (Fig. 1.29). In elderly patients, who have little to no subcutaneous layer, this nerve sits only millimeters below the skin surface. The major effect of injuring the nerve is flattening of the forehead with drooping of the eyebrow and inability to close the eye tightly. Descent of the brow into the orbital area

may interfere with upward and lateral gaze, which can be repaired with a brow-lift.

The other branch of the facial nerve at risk because of its superficial location is the marginal mandibular branch as it exits the inferoanterior pole of the parotid gland at the angle of the mandible, and as it courses upwards posterior to the facial artery onto the face just anterior to the masseter muscle to innervate the lip depressors. As the marginal mandibular nerve crosses the angle of the mandible, it is covered only by skin, subcutaneous fat, and the SMAS. Usually, the marginal mandibular nerve remains at or above the lower level of the mandible in its course. However, in 20% of people, this nerve is found to descend 1–2 cm into the neck at the mandibular angle, so caution must be exercised in this area (Fig. 1.30).<sup>23</sup> When the head is hyperextended in the opposite direction to expose the submandibular area for surgery, the nerve may be as much as 2 cm or more below the mandible, even in patients in whom this is not usually the case. In performing liposuction of the neck, it is possible to injure the marginal mandibular nerve. If the nerve is “bruised,” the patient will have an irregular smile for 6 weeks. If the nerve is transected, then there is permanent loss of the ability to smile and whistle. The platysma muscle is superficial to the marginal mandibular branch and may protect it from trauma. Unfortunately, the platysma muscle is highly variable and not always clearly identifiable. Trauma to the marginal mandibular branch can produce appreciable functional and cosmetic deficits, allowing lateral and upward pull on the mouth. The ipsilateral side tends to be frozen in a persistent grimace because of the lack of opposing downward muscular contraction.



**FIGURE 1.30** The marginal mandibular nerve descends into the neck. The surgical instrument is placed below the nerve to demonstrate the location of the nerve in this cadaver dissection. (After Robinson JK. Basic cutaneous surgery concepts. In: Robinson JK, Arndt KA, LeBoit PE, Wintroub BU, eds. *Atlas of cutaneous surgery*. Philadelphia: Saunders; 1996:1–4, with permission from Saunders.)

## Lymphatics of the head

The vessels of the lymphatic system tend to parallel the venous system and have valves every 2–3 mm. In general, the drainage is from superficial to deep, and from medial to lateral, and caudad in a downward diagonal direction. It has been estimated that between 20% and 50% of normal individuals have palpable benign lymph nodes in the neck. These lymph nodes are generally less than 1 cm in size.<sup>24</sup>

The major facial lymph node basins of the head and neck are in the parotid, submandibular, and submental areas. The major lymphatic drainage of the face consists of channels that run posteriorly in a downward diagonal direction. The scalp and posterior aspect of the ear drain to the postauricular and occipital nodes, which then drain to the deeper cervical lymph nodes of the spinal accessory, transverse cervical, and internal jugular nodes. Although the parotid nodes are identified as being both preauricular and infra-auricular, they are both within the gland and in the surrounding glandular fascia, and behave as a single unit serving the basin of the lateral cheek, anterior surface of the ear, forehead, and lateral canthal area. The submental nodes drain their respective side of the medial and lower face, the medial eyelid, the lateral aspects of the lip, the nose, the gingivae of the mouth, the soft palate, the anterior two-thirds of the tongue, and the palatine fossa. The submental glands are in the midline and have the potential to drain from either the right or left central facial region of the middle two-thirds of the lip and the chin. The submental and submandibular nodes are surrounded by glandular fascia.

The parotid nodes are examined with the patient seated and directly facing the physician, but the submental and submandibular nodes are best palpated with the chin drawn inferiorly to relax the platysma muscle overlying these areas. This procedure may be further enhanced by a bimanual examination with one finger placed in the floor of the mouth and the fingers of the other hand pressing upward against the submental and submandibular basin. The submental nodes are often palpable in healthy people.

Drainage to the postauricular nodes is from the upper posterior aspect of the ear, and the posterior parietal, mastoid, and temporal areas of the scalp. From here, drainage continues into the nodes beneath the upper portion of the sternocleidomastoid muscle and the superior junction of the internal jugular and spinal accessory node chains. The occipital nodes drain the muscular layers of the neck and posterior aspect of the scalp. They then also drain into the cervical lymph node chain (Fig. 1.31). Ultimately, the lymphatic system of the head and neck blend into a solitary trunk that empties into the venous circulation by the thoracic duct on the left and the jugular and subclavian veins on the left.

## Topographic landmarks of the ear

With the exception of the lobule, the landmarks of the ear (Fig. 1.32) are formed by the shape of the auricle, which stems from a single piece of elastic cartilage. The usual adult non-Hispanic white ear is approximately 6.5 cm in length and 3.5 cm in width. The African ear is generally shorter and the Asian ear is generally longer. Abnormal protrusion occurs in about 5% of the non-Hispanic white population.

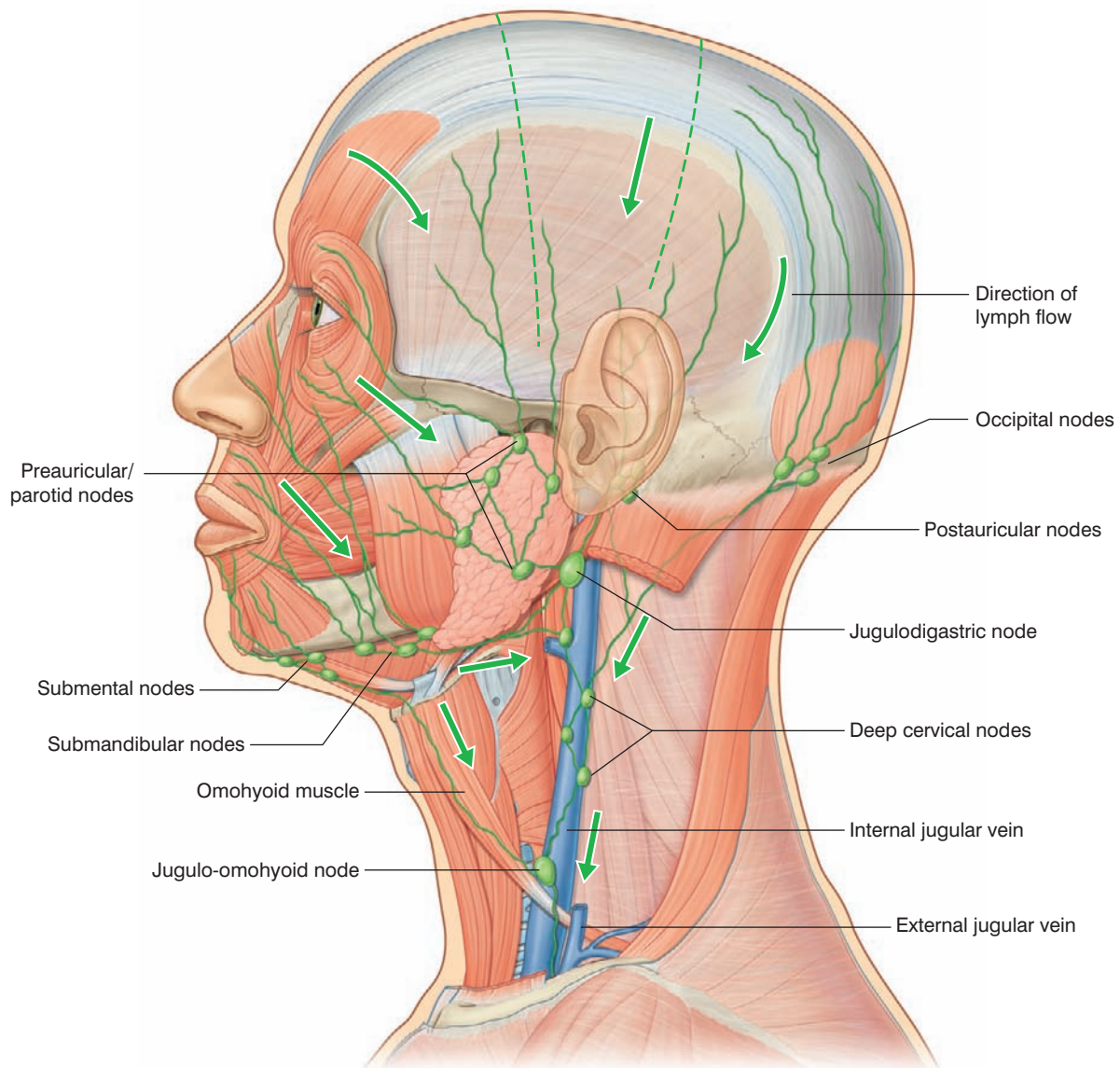
## Surgical anatomy of the neck

The skin of the neck is relatively loose with transverse creases and wrinkles. Elective incisions are easily placed in these lines. Because of the concave shape of the neck, vertical incisions have a tendency toward scar contracture with web formation, which may have functional as well as cosmetic implications.

The superficial landmarks of the neck are the hyoid bone anteriorly and the sternocleidomastoid muscle laterally, which divides the neck into the anterior and posterior triangles. The posterior triangle of the neck is important to identify because the spinal accessory nerve, which innervates the trapezius muscle, emerges from the posterior aspect of the sternocleidomastoid there. The spinal accessory nerve, which is covered only by skin and superficial cervical fascia, is vulnerable to injury during surgery in the posterior triangle. Trauma to the nerve results in loss of function of the trapezius muscle, with winging of the scapula, inability to shrug the shoulder, difficulty abducting the arm, and chronic shoulder pain. Unlike the distal aspects of the facial nerve, when this nerve is transected, it has no ability to regenerate. It exits behind the sternocleidomastoid muscle and travels diagonally in a downward direction across the posterior triangle to innervate the trapezius muscle. The exit of the spinal accessory nerve from the sternocleidomastoid muscle is known as Erb's point (Fig. 1.33).

Erb's point is located by turning the head away and bisecting a horizontal line connecting the angle of the jaw to the mastoid process with a vertical line drawn from the mid-point to the posterior border of the sternocleidomastoid muscle. If a vertical line is dropped 6 cm from the mid-point of this line, it will intersect the sternocleidomastoid muscle near to the point of emergence of the nerve.<sup>25</sup>





**FIGURE 1.31** Lymphatic system of the head and neck. Dashed lines indicate the borders between the drainage areas and arrows indicate the direction of lymph flow. (After Robinson JK. Basic cutaneous surgery concepts. In: Robinson JK, Arndt KA, LeBoit PE, Wintroub BU, eds. *Atlas of cutaneous surgery*. Philadelphia: Saunders; 1996:1–4, with permission from Saunders.)

Another way of identifying this area is to draw a horizontal line from the thyroid notch across the neck through the posterior triangle; 2 cm above and below the point where this line intersects the posterior margin of the sternocleidomastoid muscle is the approximate site where the spinal accessory nerve traverses the posterior triangle of the neck.

## Superficial anatomy of the hand and foot

Dermatologic surgery of the hand and foot is generally limited to surgery of the skin and subcutaneous tissue. In planning a procedure in these areas, every effort must be made to preserve function. Vital structures, including

nerves, arteries, veins, ligaments, and tendons, sit superficially below a thin layer of skin and fat and are often palpable. The loose dorsal skin and fascia of the hand and foot become tight when in full flexion. Procedures are planned with this in mind, so as to avoid placing undue tension on wound edges that might limit range of motion and cause wound dehiscence and unsightly scarring.

The dorsal surface of the hand is innervated by the sensory branch of the radial nerve, which is vulnerable to injury because of its superficial location, and by the dorsal branch of the ulnar nerve. Palmar skin and fascia are thick and inelastic with flexion creases ([Fig. 1.34](#)). The palmar surface is innervated by the radial, median, and ulnar nerves.

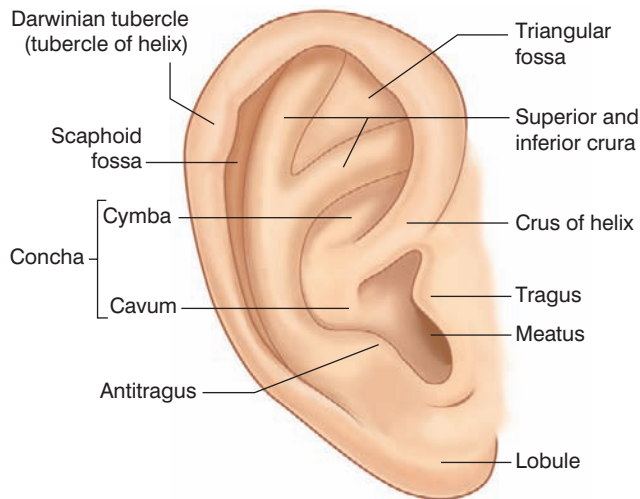


FIGURE 1.32 Topographic landmarks of the ear.

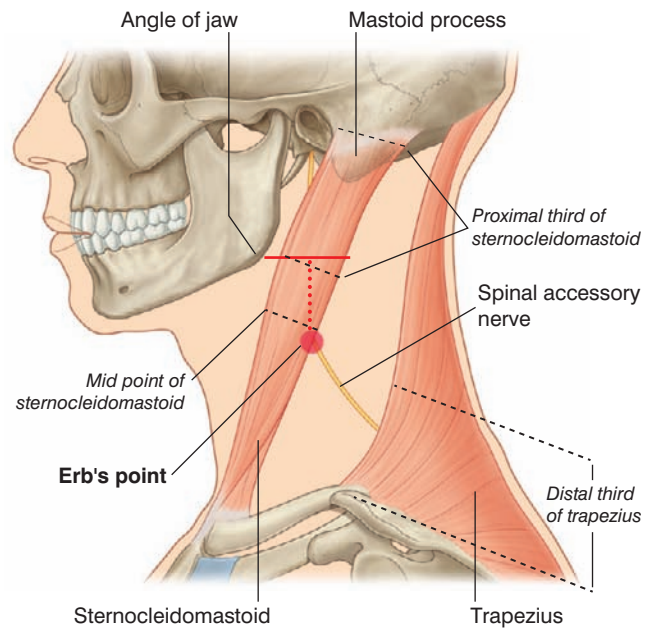


FIGURE 1.33 Erb's point is located by bisecting a horizontal line connecting the angle of the jaw to the mastoid process with a vertical line drawn from the midpoint to the posterior border of the sternocleidomastoid muscle. Within a short distance of this point, the spinal accessory nerve, lesser occipital nerve, great auricular nerve, and transverse cervical nerves all emerge from the posterior border of the muscle. (After Robinson JK. Basic cutaneous surgery concepts. In: Robinson JK, Arndt KA, LeBoit PE, Wintroub BU, eds. *Atlas of cutaneous surgery*. Philadelphia: Saunders; 1996:1–4, with permission from Saunders.)

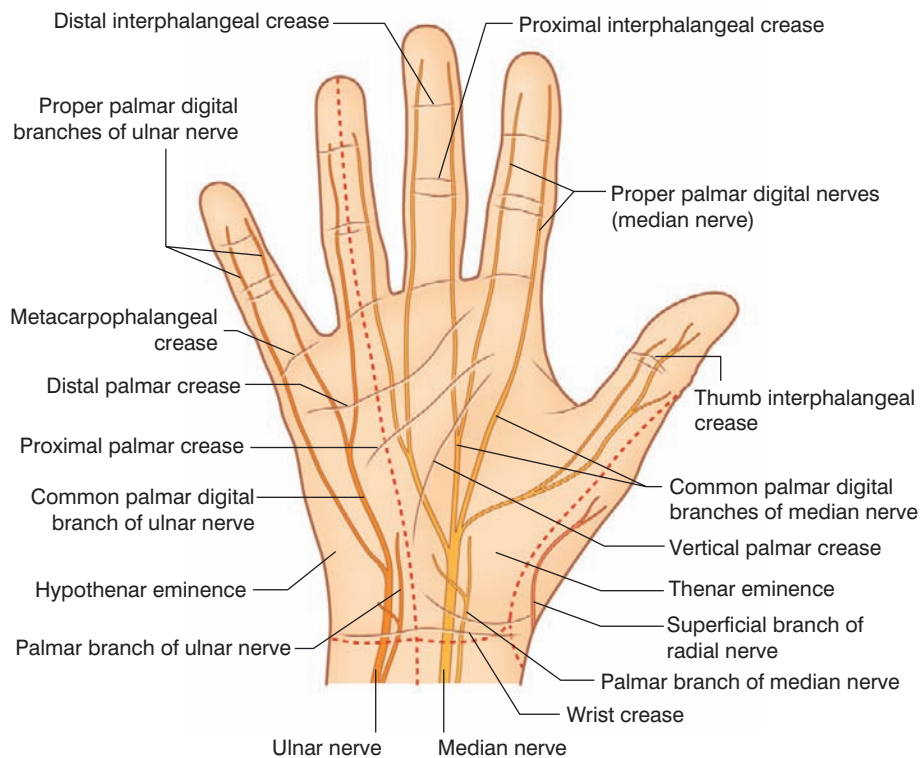


FIGURE 1.34 Palmar topographic landmarks and cutaneous innervation of the hand. Dotted lines indicate boundaries of the innervation of the palmar surface: three and one-half digits by the median nerve; one and one-half digits by the ulnar nerve. (After Robinson JK. Basic cutaneous surgery concepts. In: Robinson JK, Arndt KA, LeBoit PE, Wintroub BU, eds. *Atlas of cutaneous surgery*. Philadelphia: Saunders; 1996:1–4, with permission from Saunders.)

Palmar incisions parallel flexion creases or cross high-tension crease areas at an angle of 45° or less. Incisions that cross creases at angles approaching a right angle produce a scar that may be tender and limit movement. Transverse dorsal incisions on the dorsum of the hand are more cosmetically acceptable. Curvilinear lazy “S” incisions are better over the dorsal surface of the digits to prevent scar contracture from a longitudinal incision that may impair joint mobility. The oblique aspect of the S curve minimizes the risk of injury to longitudinal structures of the digit.

On the dorsal foot, it is preferable to make longitudinal incisions that are perpendicular to relaxed skin tension lines to avoid damaging the underlying structures. The plantar foot skin adheres to deeper structures via many fibrous bands, which make for limited tissue movement during surgery. The anatomy of the medial aspect of the foot and ankle is particularly relevant for performing posterior tibial nerve blocks (Fig. 1.35).

## Superficial anatomy of the genital area

### *Structures of the male urogenital triangle*

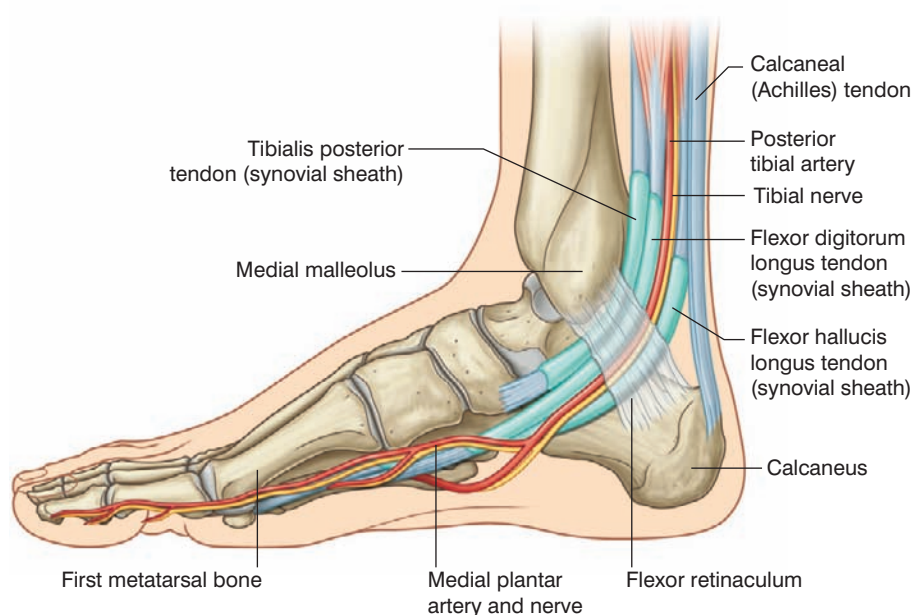
The scrotum, a cutaneous sac containing the testes, has very thin skin. The penis consists of a root and a body. The body is formed by the union of the corpus cavernosa and the corpus spongiosum (Fig 1.36). The two corpora are bounded by a thick fascia called the tunica albuginea. Buck’s fascia, a tough fascial sheath, binds all the components. The skin surrounding the body of the penis is very loose and becomes redundant at the prepuce (foreskin), but it is particularly immobile over the corona and glans (Fig. 1.37).

### *Structures of the female urogenital triangle*

The external genitalia consist of the mons pubis, labia majora and minora, vestibule, and clitoris (Fig. 1.38). The mons pubis consists of skin and subcutaneous tissue overlying the pubic symphysis. The labia majora are prominent longitudinal folds of skin supported by underlying fat. They are homologous to the male scrotum. The skin overlying the outer aspect is pigmented and hair-bearing. The labia are united anteriorly and posteriorly at the commissures. The labia minora, smaller folds within the pudendal cleft of the labia majora, surround the vaginal vestibule. Posteriorly, the labia minora unite as the frenulum of the labia (fourchette). Anteriorly, the labia split into the superior (lateral) and inferior (medial) portions. The superior portions pass above the clitoris to form the prepuce, and the inferior portions pass below the clitoris, forming the frenulum of the clitoris. The clitoris is the homologue of the male penis.

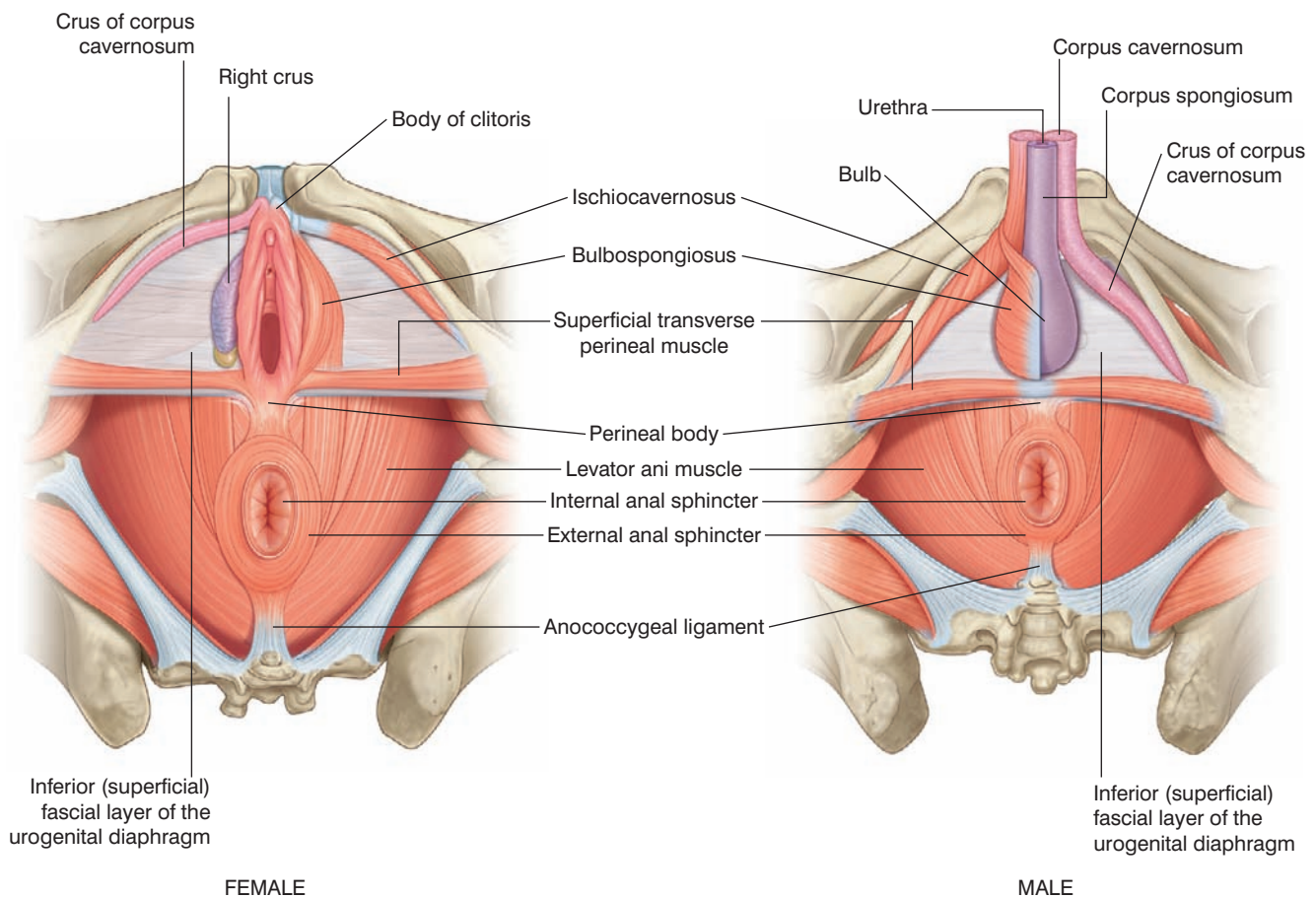
## SUMMARY

As a great deal of surgery of the skin performed by dermatologic surgeons involves the face and neck, in-depth knowledge of these areas is required to optimize outcomes and minimize patient risks. This chapter and the accompanying Expert Consult website are a source of information that would ideally be augmented and tested in cadaver dissection courses, with accurate anatomic models, and by observing surgical procedures with an experienced surgeon.

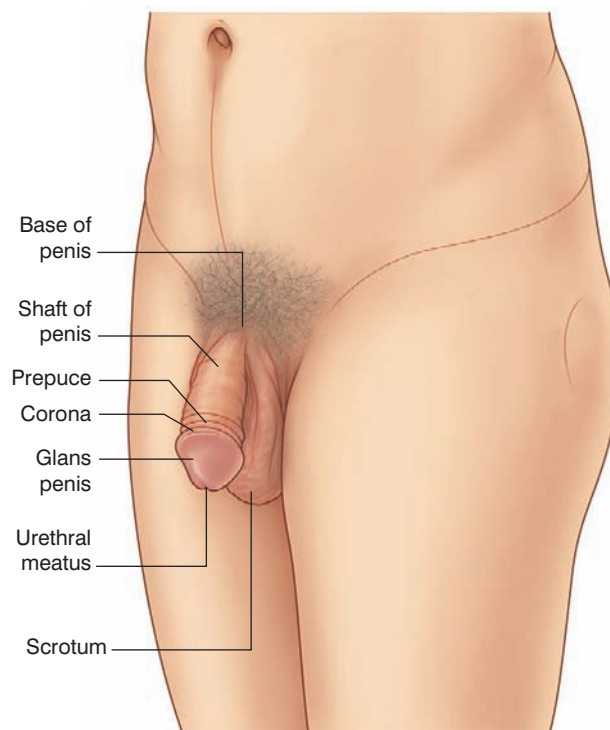


**FIGURE 1.35** Medial surface of the foot and ankle with the underlying tendons and the palpable artery. (After Robinson JK. Basic cutaneous surgery concepts. In: Robinson JK, Arndt KA, LeBoit PE, Wintroub BU, eds. *Atlas of cutaneous surgery*. Philadelphia: Saunders; 1996:1–4, with permission from Saunders.)





**FIGURE 1.36** Comparative structures of the perineum in the female and male. (After Robinson JK. Basic cutaneous surgery concepts. In: Robinson JK, Arndt KA, LeBoit PE, Wintroub BU, eds. *Atlas of cutaneous surgery*. Philadelphia: Saunders; 1996:1–4, with permission from Saunders.)



**FIGURE 1.37** Surface anatomy of the male genitalia. (After Robinson JK. Basic cutaneous surgery concepts. In: Robinson JK, Arndt KA, LeBoit PE, Wintroub BU, eds. *Atlas of cutaneous surgery*. Philadelphia: Saunders; 1996:1–4, with permission from Saunders.)

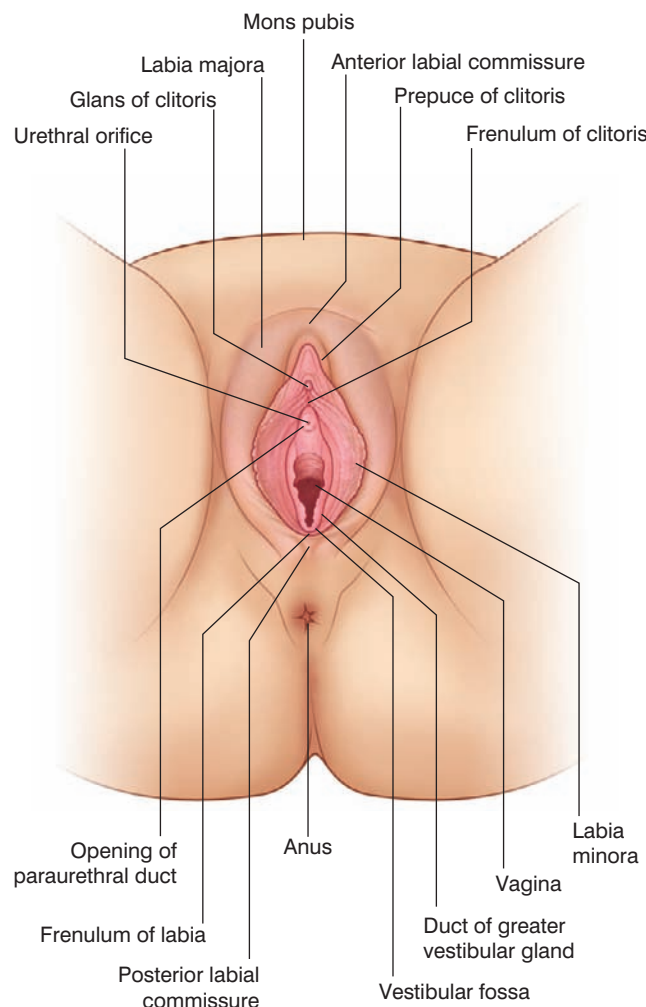


FIGURE 1.38 Surface anatomy of the female genitalia. (After Robinson JK. Basic cutaneous surgery concepts. In: Robinson JK, Arndt KA, LeBoit PE, Wintroub BU, eds. *Atlas of cutaneous surgery*. Philadelphia: Saunders; 1996:1–4, with permission from Saunders.)

### PITFALLS AND THEIR MANAGEMENT

- Facial nerve injury. When facial nerve injury is the result of blunt trauma, inflammation, or heat, the nerve may recover over a period of 2–6 months; if the loss of function does not risk loss of an important function, a period of observation is appropriate.
- Sectioning of the temporal branch of the facial nerve results in brow and lid ptosis and the inability to tightly close the eyes. Dissect above the SMAS at the temple. Botulinum toxin injections of the unaffected forehead on the contralateral side will result in the brows being at the same level. Brow-lift on the side with the brow ptosis may also be performed.
- Sectioning of the zygomatic branch causes paralysis of the upper lid resulting in epiphora and exposure keratitis. Short-term management: postoperatively, immediately provide a moisture chamber for the eye with lubrication. Long-term management: gold weight implant into the upper eyelid provides closure by gravity with lateral tarsorrhaphy; lateral canthoplasty.
- Sectioning of the marginal mandibular branch results in protrusion of the corner of the lower lid. Botulinum toxin injections of the unaffected side. Suspension of the lid at the commissure or facial nerve graft if the transection is distal may provide relief.
- Spinal accessory nerve injury. When planning surgery, locate Erb's point by turning the head away and bisecting a horizontal line connecting the angle of the jaw to the mastoid process with a vertical line drawn from the midpoint to the posterior border of the sternocleidomastoid muscle. A vertical line is dropped 6 cm from the midpoint of this line and it will intersect the sternocleidomastoid muscle near to the point of emergence of the nerve.
- Arterial bleeding. When approaching areas where there is likely to be arterial bleeding, have two hemostats available for each artery in the field; palpate the area to feel the pulsation of the artery at the inferior mandibular rim and the temple; undermine in the plane with the least risk of transecting arteries; on the scalp, undermine in the subgaleal space, and on the forehead below the muscle and over the periosteum; undermine the wound edges to see the artery and clamp it before cutting it. Ligature arteries.

## REFERENCES

- Farmer ER, Hood AF. *Pathology of the skin*. Norwalk, CT: Appleton & Lange; 1990. p. 3–29.
- Ha RY, Nojima K, Adams WP, et al. Analysis of facial skin thickness: defining the relative thickness index. *Plast Reconstr Surg* 2005;**115**:1769–73.
- Eyre DR. Collagen: molecular diversity in the body's protein scaffold. *Science* 1980;**207**:1315–22.
- Uitto J, Olsen DR, Fazio MJ. Extracellular matrix of the skin: 50 years of progress. *J Invest Dermatol* 1989;**92**:61S–77S.
- Marcus J, Horan DB, Robinson JK. Tissue expansion: past, present, and future. *J Am Acad Dermatol* 1990;**23**:813–25.
- Greener EH, Harcourt JK, Lautenschlager EP. *Materials science in dentistry*. Baltimore: Williams and Wilkins; 1972. p. 46–52.
- Larrabee WF Jr. A finite element model of skin deformation. I. Biomechanics of skin and soft tissue: a review. *Laryngoscope* 1986;**96**:399–405.
- Larrabee WF Jr. A finite element model of skin deformation. II. An experimental model of skin deformation. *Laryngoscope* 1986;**96**:406–12.
- Chayen D, Nathan H. Anatomical observations on the subgaleotic fascia of the scalp. *Acta Anat* 1974;**87**:427–8.
- Dzubow LM. *Facial flap – biomechanic and regional applications*. Norwalk, CT: Appleton & Lange; 1989.
- Robinson JK. Basic cutaneous surgery concepts. In: Robinson JK, Arndt KA, LeBoit PE, Wintroub BU, editors. *Atlas of cutaneous surgery*. Philadelphia: Saunders; 1996. p. 1–4.
- Salasche SJ, Bernstein G, Senkarik M. *Surgical anatomy of the skin*. Norwalk, CT: Appleton & Lange; 1988.
- Menick FJ. Defects of the nose, lip, and cheek: rebuilding the composite defect. *Plast Reconstr Surg* 2007;**120**:887–98.
- Jacono AA. A new classification of lip zones to customize injectable lip augmentation. *Arch Facial Plast Surg* 2008;**10**:25–9.
- Savar LM, Menghani RM, Chong KK, et al. Eyebrow tissue expansion. *Arch Ophthalmol* 2012;**130**:1566–9.
- Rohrich RJ, Pessa JE. The fat compartments of the face; anatomy and clinical implications for cosmetic surgery. *Plast Reconstr Surg* 2007;**119**:2219–27.
- Pils U, Anderhuber F. The chin and adjacent fat compartments. *Dermatol Surg* 2010;**36**:214–18.
- Naini R. Leonardo da Vinci's aesthetic analysis of nasal tip prominence. *Arch Facial Plast Surg* 2012;**14**:463–4.
- Ellis DA, Pellausa EO. Cosmetic evaluation of the lower third of the face. *Facial Plast Surg* 1987;**4**:159–64.
- Owsley JQ Jr. SMAS–platysma face lift. *Plast Reconstr Surg* 1983;**71**:573–6.
- Gassner HG, Rafii A, Young A, et al. Surgical anatomy of the face: implications for modern face-lift techniques. *Arch Facial Plast Surg* 2008;**10**:9–19.
- Holmes WD, Finch JJ, Snell D, Sloan SB. The trigeminocardiac reflex and dermatologic surgery. *Dermatol Surg* 2011;**37**:1793–7.
- Dingman RO, Grabb WC. Surgical anatomy of the mandibular ramus of the facial nerve based on the dissection of 100 facial halves. *Plast Reconstr Surg* 1962;**29**:266–72.
- Sage H. Palpable cervical lymph nodes. *JAMA* 1958;**168**:496–8.
- King RJ, Motta G. Iatrogenic spinal accessory nerve palsy. *Ann R Coll Surg Engl* 1983;**65**:35–7.



## 2

## Aseptic Technique

Christie R Travelute MD and Todd V Cartee MD

## CHAPTER SUMMARY

- In surgical procedures, there are four potential sources of contamination: the personnel, the surgical environment, the patient, and the instruments, with the patient's normal flora being the most common reservoir.
- Appropriate measures to ensure aseptic technique depend upon the procedure, the anatomical site of the surgical procedure, and the degree of contamination within the wound. There are basic precautions that should be adhered to, including:
  - Hand antisepsis before donning surgical gloves and after their removal
  - Caution with the application of alcohol-containing preparations because they are extremely flammable and should be allowed to dry completely before laser or electrocautery are used
  - Surgical antiseptic agents are safe and effective for preoperative skin preparation in almost all situations with the following caveats:
    - chlorhexidine gluconate is an irritant and should not be allowed to make contact with the eye or middle ear because permanent damage may occur
    - povidone-iodine must remain in contact with the skin to maintain its disinfective qualities
  - Hair removal is only indicated if the hair will obscure the surgical field or hinder proper surgical technique.

## INTRODUCTION

*When it had been shown by the research of Pasteur that the septic property of the atmosphere depended not on the oxygen or any gaseous constituent but on minute organisms suspended in it ... it occurred to me that decomposition in the injured part might be avoided ... by applying some materials capable of destroying the life of the floating particles. The material which I have employed is carbolic ... acid (Lister J. On the antiseptic principle in the practice of surgery. Lancet 1867; 2:353–356.)*

Before 1860, most surgery was performed reluctantly and with the understanding that the operation was as likely to kill the patient as the disease. Regardless of the success of the operation, the vast majority of patients died within a few days from overwhelming sepsis. Although less than 150 years ago, this was a time when the prowess of a surgeon

was evidenced by the amount of blood encrusted on his coat.<sup>1</sup> If a scalpel became dull during an operation it was promptly sharpened on the sole of an assistant's shoe and then placed back into the wound. Lint and sawdust from the floor were used as hemostatics, surgical sponges were reused without laundering, and it was believed wound infections were generated spontaneously by exposure to air.

The modern era of surgery began in the mid-nineteenth century, with the development of anesthesia. Once the pain from surgery was conquered, surgeons were free to focus on technique rather than speed. Despite their best efforts, hospital gangrene and death remained dreaded, but frequent, outcomes of most major operations. This dismal mortality rate remained unchanged until Pasteur introduced the germ theory of disease, which would later form the basis of Joseph Lister's principles of surgical antisepsis.

In 1867, Lister deduced that "... the essential cause of suppuration in wounds is decomposition, brought about by the influence of the atmosphere."<sup>2</sup> His antiseptic surgical technique consisted of washing the surgeon's hands, instruments, operating room environment, and surgical site with carbolic acid (phenol). He also devised an atomizer, which produced a continuous mist of carbolic acid into the air during surgery. Lister published an article in 1870, which described the influence of these measures on the deplorable conditions of the surgical wards at the Glasgow Royal Infirmary, the stench of which was notorious. After 9 months of strict adherence to handwashing and carbolic acid antisepsis, there was not a single case of hospital gangrene, pyemia, or erysipelas in the entire ward.<sup>3</sup> Unfortunately, these dramatic findings were met with strong opposition from the medical community and it took almost 10 years before surgeons began to adopt his recommendations.

"Listerism," or antisepsis, markedly decreased the mortality from surgery, but the atmosphere of the surgical suite was laden with carbolic acid, which was toxic to surgeons and other personnel who were chronically exposed to its vapors. In addition, carbolic acid was caustic when applied directly to open wounds. This prompted the search for alternative antiseptics with less morbidity, such as iodine and alcohol. The next step in surgical antisepsis was the sterilization of instruments and bandages, which became possible in 1886, when von Bergmann developed a superheated steam system similar to the modern autoclave.

Sterilization of the surgeon's hands remained a challenge until Halsted introduced "boilable" rubber gloves in 1890. Mikulicz added further refinement to the aseptic technique when he described the benefits of wearing a gauze mask in 1897, and MacDonald recognized the infection risk posed by "theatre spectators" gathered around the operating table.<sup>1</sup>

Over the last 100 years, aseptic technique has evolved into a set of well-defined practices designed to reduce the risk for surgical site infection (SSI). Dermatologic surgeons perform a broad range of procedures in a variety of settings. Appropriate measures to ensure aseptic technique depend upon the invasiveness of the proposed procedure and the risk for infection. These measures range from the use of non-sterile gloves and an alcohol skin-wipe for shave biopsies, to full surgical dress and strict asepsis for liposuction. This chapter outlines the major components of the aseptic technique and their applicability to dermatologic surgery.

## Normal flora

The human body is colonized with microorganisms that are collectively known as indigenous or normal flora. The density and composition of these microorganisms vary with different anatomic locations on the body, and on the skin are largely determined by local humidity and lipid content. Skin flora can be divided into two distinct populations: resident flora and transient flora.

### Resident flora

Resident flora have stable population densities and can be isolated in similar numbers from most individuals. These symbiotic microorganisms help protect the host from infection by competing with pathogens for substrate and tissue receptors. Resident flora inhabit the surface of the skin, as well as deeper structures, such as the pilosebaceous unit. Deeply embedded organisms are resistant to mechanical removal and are beyond the reach of topical antiseptic solutions. Given this inherent limitation, the goal of preoperative skin cleansing is to decrease resident flora to its lowest possible level, with the realization that it cannot be completely eradicated.

The most common resident organisms are the coagulase-negative staphylococci, with *Staphylococcus epidermidis* accounting for more than 90% of resident aerobes.<sup>4</sup> Anaerobic diphtheroids such as *Propionibacterium acnes* are common in lipid-rich locations, such as the pilosebaceous unit. Gram-negative bacteria represent a small portion of the resident flora. They are mostly limited to the humid intertriginous areas with *Enterobacter*, *Klebsiella*, *Escherichia coli*, and *Proteus* spp. being the predominant organisms.<sup>5</sup>

### Transient flora

Transient flora are acquired through contact with people, objects, or the environment. They are loosely attached to the surface of the skin and are amenable to removal by

washing. The majority of postoperative wound infections are due to transient microorganisms that contaminate the wound during surgery. In most cases, the source is the endogenous flora of the patient's nose, throat, or skin.<sup>6</sup> Exogenous sources of contaminating flora include the surgical personnel, the local environment (including air), surgical instruments, and materials brought into the sterile field during surgery. Based on the Centers for Disease Control and Prevention (CDC) data examining all types of SSIs, *Staphylococcus aureus* (*S. aureus*) is the most frequent organism isolated, followed by coagulase-negative staphylococci, *Enterococcus* spp., *E. coli*, group A streptococci and *Pseudomonas aeruginosa*.<sup>5,7</sup>

Most pathogens are transmitted via one of four basic routes: contact, air-borne, vehicle, or vector. For surgical procedures, the contact and air-borne routes are the most likely means of contamination. Contact transmission may be indirect where organisms are transferred via fomites (e.g., if a suture touches contaminated skin and is then placed into the wound) or direct (if contaminated skin of the patient or surgeon touches the wound). During air-borne transmission, microorganisms are not suspended freely but carried on desquamated skin cells, aerosolized water droplets, or dust particles.<sup>8</sup> In this way, the gowns, linens, surgical tables, and operating room floors are easily contaminated, particularly with staphylococci and enterococci, which are resistant to desiccation.

Despite the numerous potential causative agents of SSIs enumerated above, the predominant pathogen responsible for infection in clean skin surgery is *S. aureus* and its source is most frequently the patient's anterior nares. Of the US population, 31.6% are nasal carriers of *S. aureus* at any given time,<sup>9</sup> and nasal carriers have a 3–9.6-fold increased risk of SSIs.<sup>10,11</sup> Furthermore, among patients who develop staphylococcal SSIs and are also nasal carriers, 85% of isolates are genetically identical between the two sites, confirming the endogenous nature of the SSI.<sup>12</sup>

## Surgical site infection

The CDC defines SSI as any surgical wound that produces pus (suppurates) within 30 days of the procedure, even in the absence of a positive culture.<sup>13</sup> An exception to this rule would be a suture abscess, which may suppurate but which resolves with the removal of the suture and is not considered to be a wound infection. Inflammation is frequently associated with wound infection but, in the absence of supuration, is not sufficient to classify the wound as infected. A positive culture does not necessarily confirm a wound infection, because chronic wounds may be colonized but not infected. In this case, it is the quantity of bacteria per gram of tissue (usually  $>10^5$ ) that determines whether infection is present.

### Categories of risk

The risk for developing an SSI can be categorized by the degree of contamination within the wound.<sup>14</sup> Wounds are defined as clean if they are elective incisions carried out on

non-inflamed tissues under strict aseptic technique and if there is no entry into the gastrointestinal, respiratory, or genitourinary tracts. If there are minor breaks in aseptic technique, or entry into the gastrointestinal, respiratory, or genitourinary tracts, the wound is considered to be clean-contaminated. Contaminated wounds include those where major breaks in aseptic technique have occurred, or there is inflammation, but no frank purulence encountered. A dirty wound contains frank purulent fluid such as an abscess. It may also involve the perforation of a viscus or fecal contamination.

In addition to the local condition of the wound, patient and operative characteristics may influence the risk for developing an SSI. For example, biopsies performed in a hospital ward, as opposed to an outpatient setting, have a higher risk for infection.<sup>15</sup> A comprehensive method, such as that proposed by the CDC, incorporates additional factors such as the patient's age, malnutrition, obesity, hypothermia, use of immunosuppressants (including alcohol), and the length of the procedure.<sup>14</sup>

## PRINCIPLES OF ASEPTIC TECHNIQUE

In its *Guideline for Prevention of Surgical Site Infection*, the CDC exhorts that "rigorous adherence to the principles of asepsis by all scrubbed personnel is the foundation of surgical site infection prevention."<sup>16</sup> However, the need for strict aseptic technique during clean dermatologic surgery has been called into question. For example, infection rates using non-sterile gloves for Mohs surgery are low and comparable with those using complete sterile technique.<sup>17-19</sup> In reality, a wide range of "clean" and "modified sterile" techniques are commonly employed for most dermatologic procedures. As the complexity and invasiveness of the procedure increases, so does the need for adherence to strict surgical asepsis. This chapter will discuss the proper execution of both clean and sterile techniques in dermatologic surgery in the office setting, focusing on those key principles that are generally applicable to dermatologic surgeons.

Aseptic technique involves preoperative preparation to create a sterile field and then maintenance of sterility throughout the procedure. Creation of a sterile field is comprised of three elements: (1) preparation of the surgical personnel, (2) preparation of the patient, and (3) preparation of the instruments and operating environment. The first two of these necessitate the use of antiseptic agents, which will be reviewed first.

### Antiseptic agents

The ideal antiseptic agent should be broad-spectrum, non-irritating, fast-acting, and provide continued antimicrobial action within the moist environment of the surgical glove. There are several commercially available antimicrobial ingredients approved for either surgical hand antisepsis,

surgical site preparation, or both. Each agent has its own unique characteristics and action spectrum but none is ideal for every situation. A thorough working knowledge of the strengths and limitations of these ingredients is essential to choosing the appropriate agent for each setting (Table 2.1).

In the USA, the most common agents are iodophors, chiefly povidone-iodine (PI), and chlorhexidine gluconate with and without alcohol. PI is a broad-spectrum antiseptic with well-known skin- and fabric-staining qualities. It works within minutes but must be left on the skin to have a persistent effect. It is quickly inactivated in the presence of blood or sputum, and chronic maternal use has been associated with hypothyroidism in newborns.<sup>20</sup> PI is available as a 10% aqueous solution and a 7.5% foaming surgical scrub (Betadine®, Purdue Products L.P., Stamford, CT). The scrub contains a detergent, which should not be allowed to make contact with the eyes. Prolonged skin contact with wet PI solution can induce irritant and rarely allergic contact dermatitis but once dried, it is generally non-irritating and can be left on the skin and covered with a dressing.<sup>21</sup> While approved for use on other mucous membranes, the label for PI 10% aqueous solution states "Do not use in the eyes." Consequently, Alcon (Fort Worth, TX) markets a specific ophthalmic preparation of PI (Betadine® 5% Ophthalmic Prep Solution). However, 10% PI solution diluted 1:1 with normal saline is commonly used off-label for surgical antisepsis of the conjunctiva and periocular skin. This approach is based on extensive safety and efficacy data for bacterial endophthalmitis prophylaxis in cataract surgery.<sup>22</sup> It is felt that the full strength 10% PI solution causes conjunctival irritation but direct comparative data is lacking.

Chlorhexidine gluconate (CHG) has a similar antimicrobial spectrum as PI. CHG binds to the stratum corneum and maintains residual activity in excess of 6 h, even when wiped from the field. Its action is not affected by the presence of organic matter, but it should be used with caution around the eyes, as it can cause conjunctivitis and severe corneal ulceration (see below).<sup>23</sup> CHG can also induce ototoxicity if allowed to reach the middle ear through a perforated tympanic membrane. Animal studies and human case reports describe resultant deafness from prolonged exposure of CHG to the middle ear.<sup>24,25</sup> Application to the pinna and even the external auditory meatus does not pose a risk to patients with an intact tympanic membrane but, as the status of the membrane is generally unknown, it is prudent to avoid dripping the solution into the auditory canal. CHG comes in a wide variety of strengths and formulations, the full menu of which is beyond the scope of this chapter. The most common formulation in dermatologic use is the 4% scrub solution (Hibiclens®, Mölnlycke Health Care, Norcross, GA or generic equivalents), which is used for surgical hand scrub as well as skin preparation.

Both CHG and iodophors are available in alcoholic solutions (ChlorPrep®, CareFusion Corporation, San Diego, CA and DuraPrep®, 3M, St. Paul, MN), which are FDA approved for one-step preoperative skin preparation.

**Table 2.1** Common antiseptic agents

Agent	Action spectrum <sup>a</sup>	Rapidity of onset	Sustained activity	Cautions
60–95% Alcohols	++++ Gram-positive ++++ Gram-negative +++ <i>M. tuberculosis</i> +++ Fungi +++ Enveloped viruses	Fastest	Minimal as a single agent	Flammable Poor cleansing agent Use liberal amount and allow to dry
Chlorhexidine gluconate	++++ Gram-positive +++ Gram-negative + <i>M. tuberculosis</i> ++ Fungi +++ Enveloped viruses	Fast	Excellent Additive effect with repeated use	Ocular toxicity with conjunctivitis and severe corneal ulceration Ototoxicity
Povidone-iodine	++++ Gram-positive +++ Gram-negative +++ <i>M. tuberculosis</i> +++ Fungi +++ Enveloped viruses	Fast	Intermediate to minimal if wiped from the skin	Potential systemic toxicity with neonates or large body surface area Rapidly neutralized by blood, serum proteins, or sputum
Parachlorometaxylenol (PCMX)	+++ Gram-positive ++ Gram-negative <sup>b</sup> ++ <i>M. tuberculosis</i> ++ Fungi ++ Enveloped viruses	Intermediate	Intermediate to excellent depending on formulation	Poor <i>Pseudomonas</i> coverage as a single agent

<sup>a</sup>Spectrum of action: ++++ excellent; +++ good; ++ fair; + poor.  
<sup>b</sup>Improved *Pseudomonas* coverage with addition of chelating agent such as EDTA.  
 Adapted from Wade and Casewell<sup>85</sup> and Parienti et al.<sup>33</sup>

DuraPrep<sup>®</sup> was approved in 2006 and contains iodine povacrylex, an iodophor related to PI but with 74% isopropyl alcohol and more persistent activity as per its manufacturer. ChlorPrep<sup>®</sup>, approved in 2000, contains 2% CHG in 70% isopropyl alcohol. The addition of alcohol, a broad-spectrum antiseptic in its own right, greatly increases the speed of action, while maintaining the residual activity of the antiseptic.<sup>16</sup> These one-step agents are only available packaged in single use applicators, which has limited their routine use in dermatologic surgery, but they are widely used in hospitals. Alcohol is irritating to mucous membranes and therefore these agents must be used cautiously around the eyes or mouth.

While available data supports the use of both PI and CHG, whether either agent provides superior SSI prophylaxis over the other remains an open debate. An influential randomized trial found preoperative skin preparation with CHG-alcohol decreased SSIs after clean-contaminated surgery by 41% compared with a traditional PI scrub and paint.<sup>26</sup> Other studies have also shown superior results with CHG-alcohol.<sup>27</sup> However, these studies have been criticized for comparing a combination of two potent antiseptics (alcohol and CHG) with a single agent (PI).<sup>28</sup> Indeed, some studies of iodophor-alcohol combination products have shown similar antimicrobial efficacy to CHG-alcohol.<sup>29</sup> In a prospective randomized study relevant to dermatologic surgery, Veiga and colleagues compared the outcomes of PI-alcohol and CHG-alcohol solutions when used prior to clean plastic surgery.<sup>30</sup> CHG-alcohol significantly reduced bacterial colonies at the end of surgery and also reduced

SSIs, although not quite to the level of statistical significance ( $p=0.06$ ). While the results overall are conflicting and complicated by the use of varied antiseptic formulations in non-standardized situations, the overall weight of the evidence tends to favor a slight superiority in infection control for CHG over PI. Furthermore, CHG or iodophor-alcoholic formulations are likely superior to their aqueous counterparts and might be preferable for dermatologic surgery in areas prone to higher rates of infection such as the groin or lower leg.

Preparations with alcohol as the sole antiseptic agent are the standard of care in Europe for surgical hand antisepsis and are gaining popularity in the USA.<sup>31</sup> Multiple studies have confirmed their safety, speed, and broad range of antimicrobial activity.<sup>32,33</sup> Alcohol-based solutions do not necessarily have detergent qualities and should only be applied to clean skin and fingernails.<sup>34</sup> Alcohol-containing products are highly flammable and should be allowed to dry before electrocautery or a laser is used (Figs 2.1, 2.2). When applied as a single agent, alcohol is rapidly germicidal, but once evaporated, it does not have significant residual activity.<sup>34</sup> For this reason, alcohol as a single agent is not commonly used for preoperative skin preparation for sterile procedures, although it is an excellent option for surgical hand antisepsis.

Parachlorometaxylenol (PCMX), also known as chloroxylenol, has good Gram-positive bacteria coverage but notably poor activity against *P. aeruginosa*. To address this limitation, several PCMX formulations have either an added chelator, such as ethylenediaminetetraacetic acid