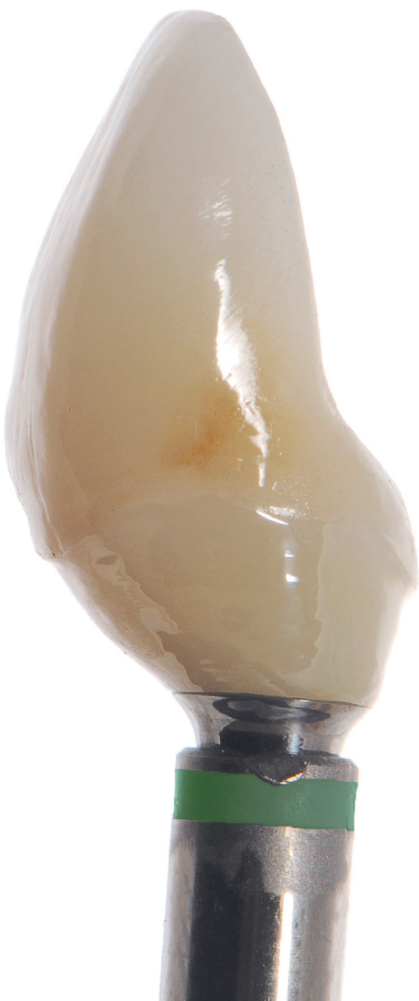

# ZERO BONE LOSS CONCEPTS

TOMAS LINKEVIČIUS, DDS, Dip Pros, PhD



## Zero Bone Loss Concepts





# ZERO BONE LOSS CONCEPTS

**Tomas Linkevičius, DDS, Dip Pros, PhD**

Professor  
Institute of Odontology  
Vilnius University

CEO and Founder  
Vilnius Research Group

Private Practice  
Vilnius, Lithuania

*With contributions from*

Algirdas Puišys, DDS, Spec Perio, PhD, and Rolandas Andrijauskas, CDT, MDT

 **QUINTESSENCE PUBLISHING**

Berlin, Barcelona, Chicago, Istanbul, London, Mexico City,  
Milan, Moscow, Paris, Prague, São Paulo, Seoul, Tokyo, Warsaw



*To my father.*

#### Library of Congress Cataloging-in-Publication Data

Names: Linkevičius, Tomas, author.  
Title: Zero bone loss concepts / Dr Tomas Linkevičius.  
Description: Batavia, IL : Quintessence Publishing Co, Inc, [2019] | Includes bibliographical references and index.  
Identifiers: LCCN 2018057839 (print) | LCCN 2018058674 (ebook) | ISBN 9780867158342 (ebbok) | ISBN 9780867157994 (hardcover)  
Subjects: | MESH: Dental Implantation--methods | Alveolar Bone Loss--prevention & control | Dental Implantation--instrumentation | Dental Implants  
Classification: LCC RK667.I45 (ebook) | LCC RK667.I45 (print) | NLM WU 640 | DDC 617.6/93--dc23  
LC record available at <https://lccn.loc.gov/2018057839>



© 2019 Quintessence Publishing Co, Inc

Quintessence Publishing Co, Inc  
411 N Raddant Road  
Batavia, IL 60510  
[www.quintpub.com](http://www.quintpub.com)

5 4 3 2

All rights reserved. This book or any part thereof may not be reproduced, stored in a retrieval system, or transmitted in any form or by any means, electronic, mechanical, photocopying, or otherwise, without prior written permission of the publisher.

Editor: Marieke Zaffron  
Design: Sue Zubek  
Production: Sue Robinson

Printed in China

# CONTENTS

Preface *VIII*

Acknowledgments *X*

Contributors *XI*

Introduction to Zero Bone Loss Concepts *XII*

## SECTION I: Surgical Concepts

1 Surgical Factors for Establishing Crestal Bone Stability 3

2 Implant Design Factors 17


3 Implant Placement Depth 33

4 Vertical Soft Tissue Thickness 43

5 Subcrestal Implant Placement 67

6 Flattening of the Alveolar Ridge 83

7 The Tent-Pole Technique 91



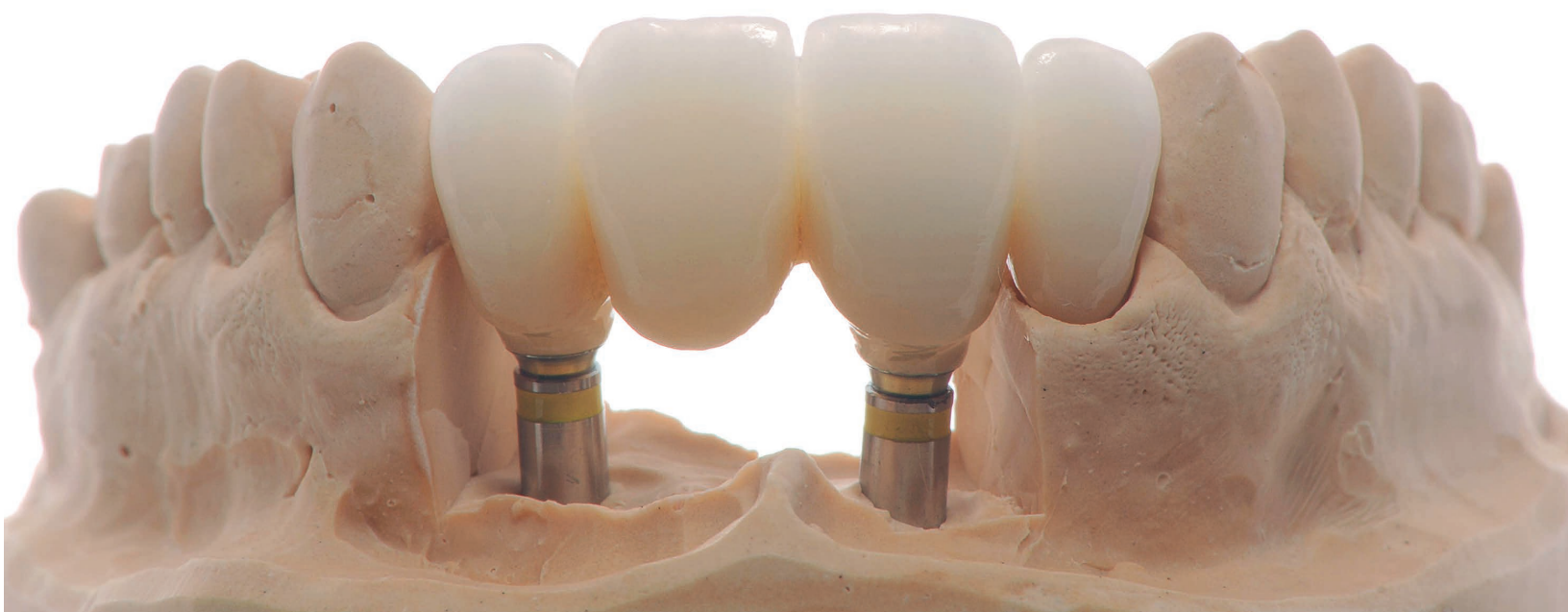

- 8 Vertical Soft Tissue Augmentation 99
- 9 Attached Tissues Around Dental Implants 117
- 10 Practical Recommendations for Implant Placement 127

## SECTION II: Prosthetic Concepts

- 11 Prosthetic Factors for Maintaining Crestal Bone Stability 137
- 12 Considerations for Cement-Retained Restorations 141
- 13 Cement/Screw-Retained Restorations 165
- 14 Titanium Base Solutions for Fixed Partial Dentures 183

15	Abutment Alternatives	199
16	Influence of the Emergence Profile	211
17	Prosthetic Materials	223
18	Subgingival Materials	227
19	Avoiding “Zirconia Without Zirconia” Restorations	251
20	Supragingival Materials for Implant Reconstructions	263
Epilogue		281
Index		282



# PREFACE

When I was a child, a dream of mine was to write a book that could be read all over the world. Therefore, when Mr Christian Haase of Quintessence Publishing offered me this opportunity, I said yes without any hesitation. Of course, as a child I did not imagine that my book would be an implant dentistry text rather than an adventure novel, but it is a good start. ☺

The possibility to publish reminded me what an excellent profession dentistry is and how you can actually combine multiple professions into a single job: You can be a clinician and treat patients; you can be a scientist and perform clinical and in vitro studies; you can be an academic who teaches students taking their first steps in dentistry; you can be a lecturer performing on international stages; and finally, you can be a writer, which allows you to summarize all your experience from these activities and put them on paper.

I had a vision for this book from the very beginning, and I'm very happy that it worked out so well. My goal was to not only fill the book with evidence-based knowledge based on top-tier publications but also to make it esthetically pleasing, because hard scientific data do not necessarily need to be boring or dry. They should be presented in an attractive manner, and this is exactly what is done here.

You might ask, who should read this book? Is it for advanced practitioners, or beginners who need basic knowledge? This question reminds me of a conversation I had with one of the participants of my course. He was an advanced clinician who successfully performed large-scale bone and soft tissue augmentations, but he was not aware that an

implant's position should be determined by its design, which—in my opinion—is basic knowledge. That surgeon was constantly losing precious bone around implants and undergoing so much effort to regain it, but a simple modification of implant position resolved the problem completely. So the answer is that this book is for all clinicians who seek to improve crestal bone stability around the implants they place and restore, because the same information could be considered advanced or basic, depending on the person.

This book is unique in the sense that it combines surgical and prosthetic advice: first how to develop crestal bone stability and then how to maintain that stability. In this way, it reflects my own professional practices. I was originally trained as a prosthodontist, and for the first 5 years of my career, my practice was limited to prosthetic work. However, I soon realized that without the proper surgical knowledge and techniques, I simply could not deliver the results that my patients deserved.

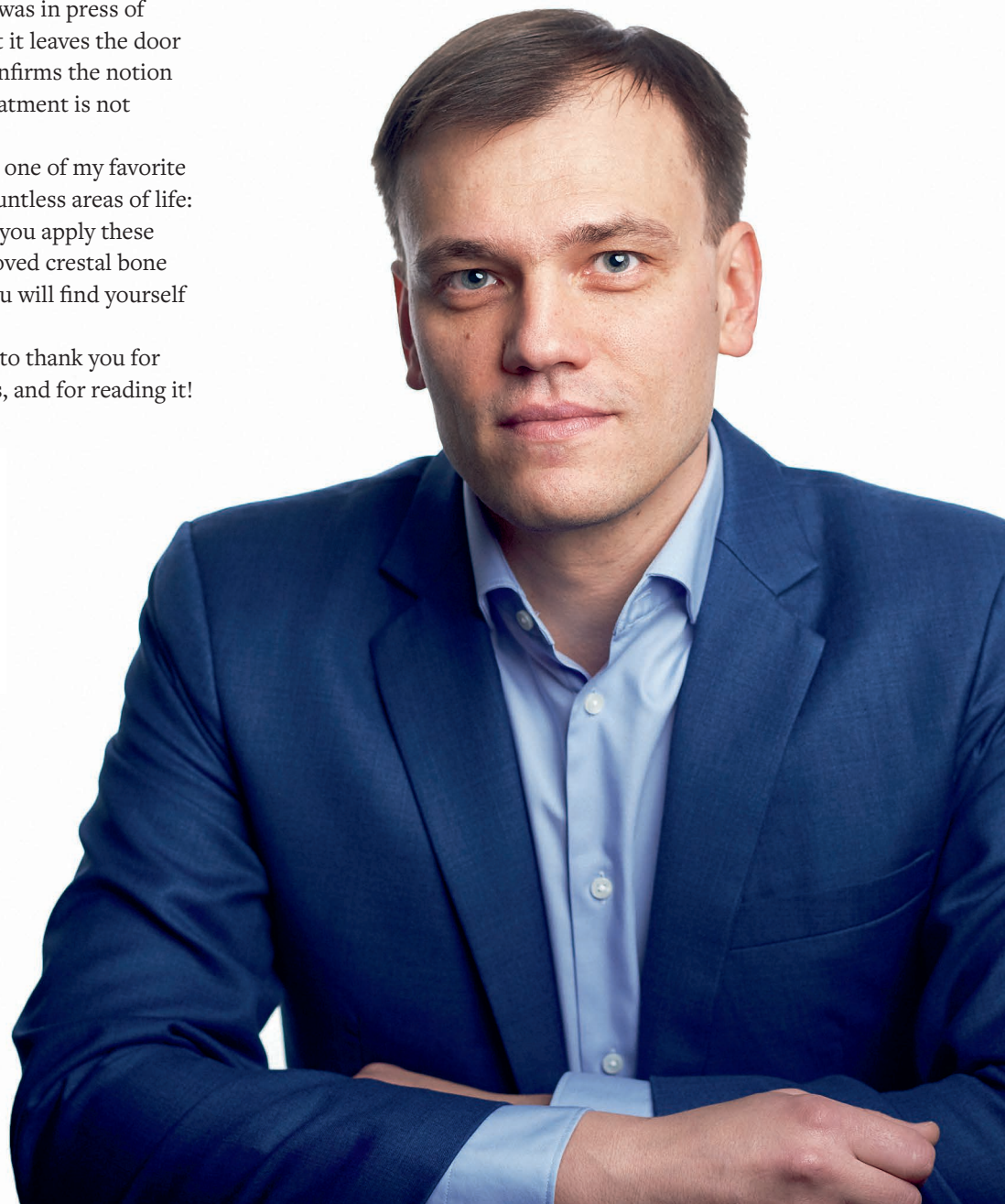
My goal has always been to provide simple solutions to complex problems. In all my research, I try to provide a clear answer to a single question. For example, which cementation margin position allows complete removal of cement remnants? The answer provided by my study was a supragingival position. Research should be conducted with its audience in mind: The clinicians who will read and apply the study should be able to understand the research. This is why I included a chapter at the end of the surgical section that provides a concise summary and why each chapter has a list of take-home messages—like those I provide in my lectures—that delivers the key points of the topic to the reader.



The process of writing this book made me conclusively understand that treatment ideas and information are constantly changing and that this process has no end. The newest research that has been generated while the book was in press of course could not make it in, but it leaves the door open for future editions and confirms the notion that the definition of “best” treatment is not permanent.

I would like to conclude with one of my favorite sayings that has held true in countless areas of life: “Impossible is nothing.” When you apply these concepts and witness the improved crestal bone levels around your implants, you will find yourself repeating this exact phrase.

Dear colleagues, I would like to thank you for holding this book in your hands, and for reading it!

A stylized, handwritten signature in black ink, featuring a large, sweeping loop on the left and a series of smaller, connected strokes on the right.

# ACKNOWLEDGMENTS

A book like this never comes out of nowhere. Reaching this achievement requires a veritable journey, and there will always be people you meet along the way who must be acknowledged.

I would first like to thank my wife, Laura, for her love and support, and our three children: Ula, Aloyzas, and Antanas. I am truly blessed with my family, who make my life so fun and fulfilling.

During my professional life, I have been so lucky to work with exceptional experts in their fields, great friends of mine and coauthors of this book. First, I want to thank my friend and partner Dr Algirdas Puišys, a talented periodontist and specialist in implant dentistry. Algirdas and I have been working shoulder to shoulder for 15 years, and only thanks to him has it been possible to develop the surgical techniques of vertical soft tissue augmentation that are presented in this book. In addition, most of the clinical cases were treated by Algirdas. Likewise, I want to thank Rolandas Andrijauskas, one of the best certified dental technicians that I have had the privilege to collaborate with. He has not only delivered the majority of the beautiful ceramic restorations and amazing enlarged pictures presented in the book, but he has also perfected the zirconia polishing technique, which is one of the key aspects in the prosthetic part of the zero bone loss concepts.

I had many excellent teachers in my life, but I want to distinguish Prof Peter Apse from Rīga, Latvia. Peter was my PhD thesis supervisor on the topic of vertical soft tissue thickness, which I defended in 2009 at Rīga Stradiņš University, Latvia. I'm thankful to Prof Apse for taking me under his wing as a young resident in prosthetic dentistry and helping me become the scientifically oriented clinician that I am now.

Further, my special thanks goes to Dr Marius Steigmann from Heidelberg, Germany, whom I met later in my career. I'm grateful for all his advice, most particularly the suggestion to put all my research together into what eventually became first a zero bone loss concepts hands-on course and now this book.

Dr Stephen Chu from New York played a significant role in the development of my concepts, likely without even realizing it. He was one of the first internationally well-known lecturers to recognize my work, and he supported me at times when I doubted the certainty of my research.

Finally, I want to thank all of my young scientific colleagues from the Vilnius Research Group, the private research center that I now supervise and that I'm sure will continue to produce groundbreaking data into the future.

# CONTRIBUTORS

**Algirdas Puišys, DDS, Spec Perio, PhD**

Vilnius Implantology Center

Vilnius Research Group

Vilnius, Lithuania

**Rolandas Andrijauskas, CDT, MDT**

Founder

MasterLab Dental Innovation and Research Center

Vilnius, Lithuania



Algirdas Puišys (*left*), Tomas Linkevičius (*middle*), and Rolandas Andrijauskas (*right*).





# INTRODUCTION TO ZERO BONE LOSS CONCEPTS

I will start with the first questions I ask during my courses and lectures: Do you have crestal bone loss around implants that you place and restore? Are you here because you want to understand why this sometimes happens? Most people I speak to respond in the affirmative: Many of their implants have some degree of bone loss. This is a major issue that can be encountered in any practice. However, crestal bone loss does not have to occur. With this idea in mind, I created *zero bone loss concepts*: the protocols to achieve the status of zero bone loss.

Zero bone loss is achievable—not just months after prosthetic delivery but years after completion of treatment. Figure 1 demonstrates an extraordinary case with results for which we constantly strive. The inevitable questions are: Why was this case so successful? What can we do to attain these outstanding results?

This is the question that I hope to answer with this book, using concepts taken from two realms: clinical practice and scientific research. However, each of these, taken individually, has its shortcomings.

## Clinical Practice

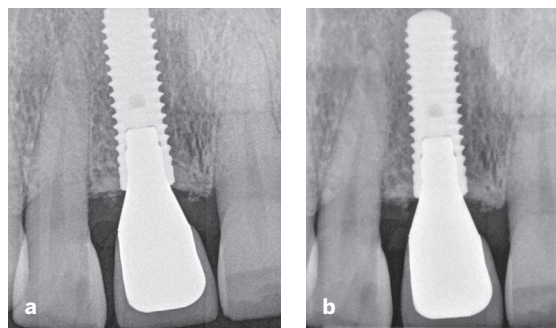
There are many books that show very successful clinical outcomes, but they are frequently based only on the authors' experiences. The results are great, but just because one clinician reports these results, it does not mean that readers will have the

same outcomes. The unfortunate response is the well-known phrase, "It works in my hands." Readers may try to mimic the results with less than desirable outcomes and then become discouraged. Usually, those readers or course participants may begin to blame themselves, questioning their ability to perform contemporary treatment. In the speaker's world, there is a new term, *podium dentistry*, which refers to clinicians presenting only their good experiences rather than the entire picture, including complications.

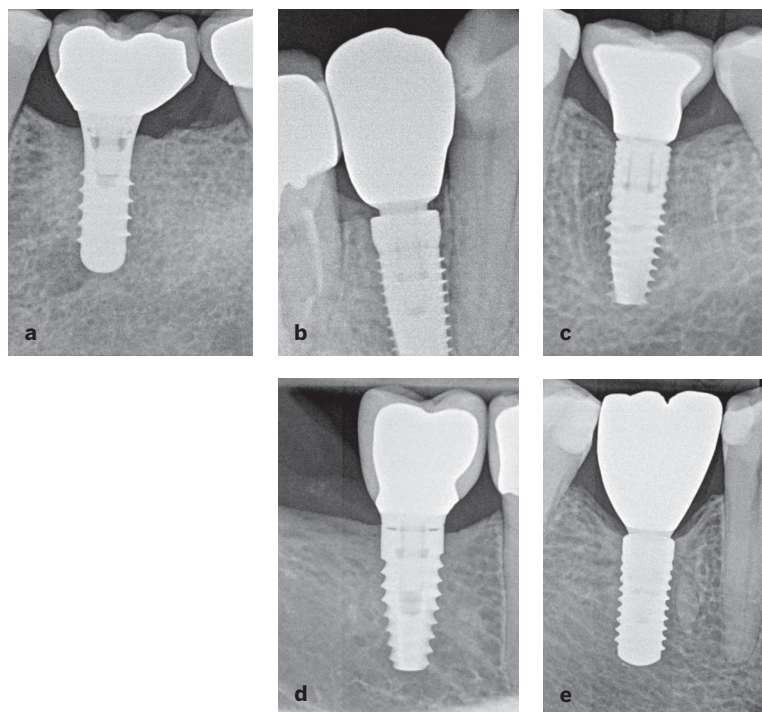
## Scientific Research

It can be a challenge for strict science to be taken seriously by the clinical world because it is often viewed as too far removed—or even boring. Evidence-based implant dentistry is of course the ideal situation, but it is seldom achieved, because the truth is that clinical studies are very difficult to perform correctly and without bias. Another challenge that arises is that ethical rules are becoming stricter, and patients are becoming more and more reluctant to take part in clinical trials. These factors have made it more difficult to get approval from ethics committees and conduct clinical trials. The result is a situation where the scientific and clinical worlds start to distrust each other, which is the worst outcome. Therefore, true success is achieved when treatment is performed based on clinical evidence with the appropriate logic and technical skills.

**Fig 1** (a) Maxillary implant in 2013. (b) The same patient in 2018.



**Fig 2** Zero bone loss concepts with different implants. (a) Straumann Tissue Level implant. (b) Conelog implant (Camlog). (c) V3 implant (MIS Implants Technologies). (d) BioHorizons Tapered implant. (e) Straumann Bone Level implant.



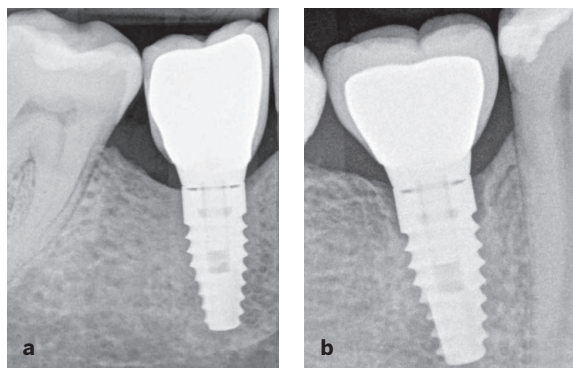
## Integration of Science and Clinical Practice

The purpose of this book is to combine these worlds—scientific and clinical—into one. This gives clinicians exactly what they need: clinical procedures backed by solid clinical evidence. That was the idea behind the development of the zero bone loss concepts.

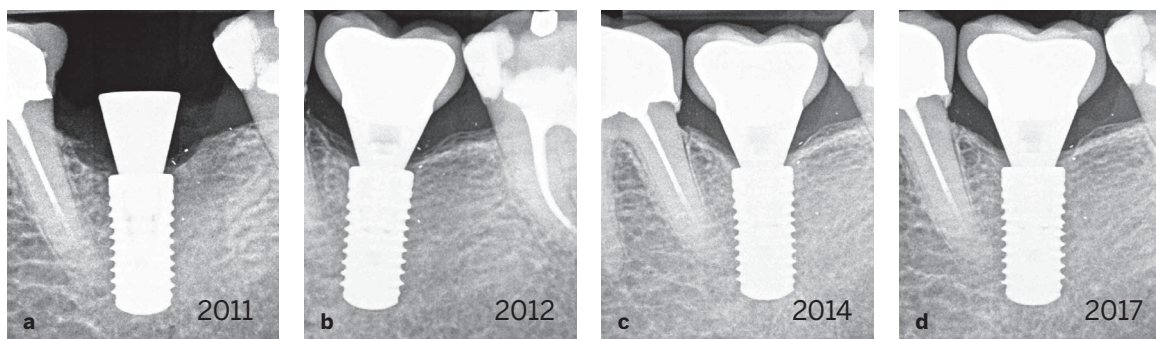
I was once confronted by a colleague with the argument that it is not possible to have zero bone loss around implants. Of course, I agreed, but explained that we must do our best to move in that

direction. We are making great progress, because one of the studies demonstrated only 0.2 mm of crestal bone loss—almost zero!<sup>1</sup>

I strongly believe that it is possible to achieve bone stability with different implant systems, surfaces, implant-abutment connections, and prosthetic solutions (Fig 2). It is even possible with or without platform switching. However, clinicians must understand the surgical and prosthetic aspects as well as the biologic and mechanical principles of implant treatment to achieve success. There have been successful and unsuccessful cases with the same implant systems (Fig 3). This highlights the fact that implant design is not the sole



**Fig 3** Crestal bone stability (a) and bone loss (b) using the same kind of implant.



**Fig 4** Long-term (7-year) follow-up of an implant placed and restored according to zero bone loss concepts. (a) Before restoration in 2011. (b) The implant with the restoration in 2012. (c) Implant status 3 years after treatment in 2014. (d) In 2017, there is bone gain around the implant.

factor involved in achieving crestal bone stability. While it is possible to achieve zero bone loss with nearly any implant system, some systems demand more work and understanding to accomplish this goal than others. The clinician must be very familiar with the implant system of choice, including its strengths and weaknesses. This is the way to success (Fig 4).

The outcome of implant treatment relies on the stability of the crestal bone, and that is the key factor that will determine whether treatment will succeed or fail. Therefore, each technique and concept in this book is focused on keeping the bone intact. The point is not to determine only the most important factors that affect bone stability but rather to discuss how the many factors work with each other and how this collaboration influences bone stability.

The techniques and concepts presented in this book are all supported by scientific studies, an overwhelming majority of which are clinical studies. My team and I have published over 20 papers

in many prestigious dental journals, including *The International Journal of Oral and Maxillofacial Implants*, *Clinical Oral Implants Research*, and *The International Journal of Periodontics and Restorative Dentistry* (Table 1). The clinical and laboratory procedures that we follow and recommend to our readers are based on scientific evidence. Rather than relying only on our own clinical experience, our protocols are backed by science. It is this marriage of science and practice that makes this book and its concepts exceptional. Another exceptional fact about the cases discussed in this book is that all clinical and in vitro studies were performed in a private practice environment. Clinical trials are usually performed at universities, but my team developed a special system in which the private practice is connected to the universities and under strict guidance to contribute to the field of knowledge in implant dentistry.

It is very important to me that this book is not based just on clinical findings and case reports; rather, it is based mostly on controlled clinical

**Table 1** List of published research supporting zero bone loss concepts

Authors	Year	Publication	Title
Linkevičius and Apse	2008	<i>Stomatologija</i>	Biologic width around implants. An evidence-based review
Linkevičius and Apse	2008	<i>The International Journal of Oral and Maxillofacial Implants</i>	Influence of abutment material on stability of peri-implant tissues: A systematic review
Linkevičius et al	2008	<i>Stomatologija</i>	Veneer fracture in implant-supported metal-ceramic restorations. Part I: Overall success rate and impact of occlusal guidance
Linkevičius et al	2009	<i>Stomatologija</i>	Reaction of crestal bone around implants depending on mucosal tissue thickness. A 1-year prospective clinical study
Linkevičius et al	2009	<i>The International Journal of Oral and Maxillofacial Implants</i>	The influence of soft tissue thickness on crestal bone changes around implants: A 1-year prospective controlled clinical trial
Linkevičius et al	2010	<i>The Journal of Oral and Maxillofacial Surgery</i>	Influence of thin mucosal tissues on crestal bone stability around implants with platform switching: A 1-year pilot study
Linkevičius et al	2011	<i>The Journal of Prosthetic Dentistry</i>	A technique for making impressions of deeply placed implants
Linkevičius et al	2011	<i>Clinical Oral Implants Research</i>	The influence of margin location on the amount of undetected cement excess after delivery of cement-retained implant restorations
Sicilia et al	2012	<i>Clinical Oral Implants Research</i>	Computer-guided implant therapy and soft- and hard-tissue aspects. The Third EAO Consensus Conference 2012
Linkevičius et al	2012	<i>The Journal of Prosthetic Dentistry</i>	The influence of implant placement depth and impression material on the stability of an open tray impression coping
Linkevičius et al	2013	<i>Clinical Oral Implants Research</i>	Does residual cement around implant-supported restorations cause peri-implant disease? A retrospective case analysis
Linkevičius et al	2013	<i>Clinical Oral Implants Research</i>	The influence of the cementation margin position on the amount of undetected cement. A prospective clinical study
Vindašiūtė et al	2015	<i>Clinical Implant Dentistry and Related Research</i>	Clinical factors influencing removal of the cement excess in implant-supported restorations
Linkevičius et al	2015	<i>Clinical Implant Dentistry and Related Research</i>	Crestal bone stability around implants with horizontally matching connection after soft tissue thickening: A prospective clinical trial



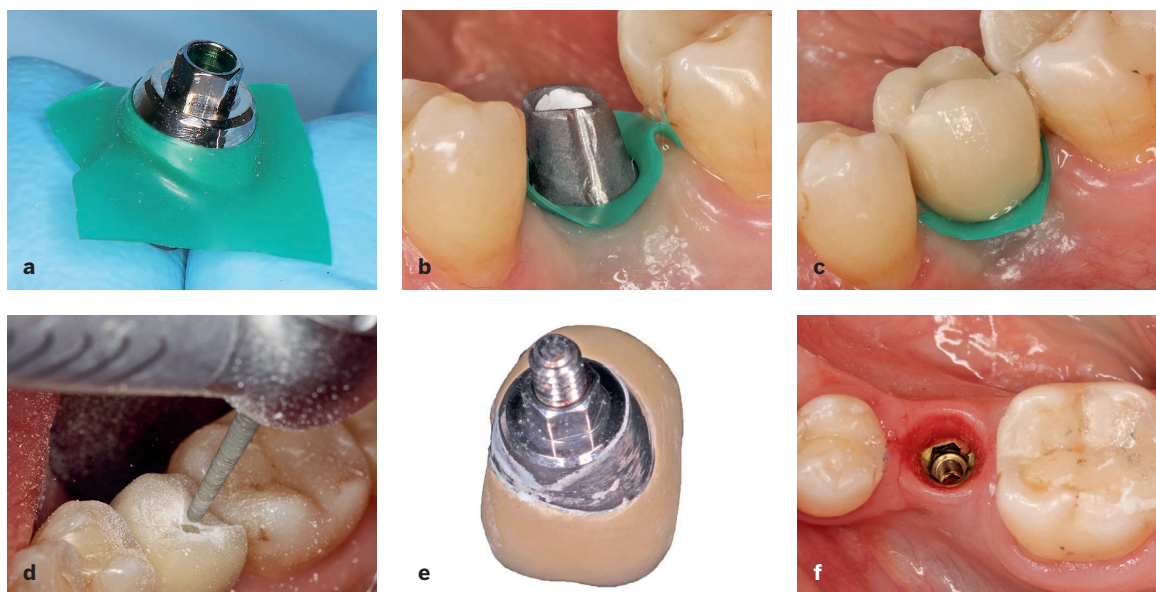
**Table 1** (cont) **List of published research supporting zero bone loss concepts**

Authors	Year	Publication	Title
Linkevičius et al	2015	<i>Clinical Implant Dentistry and Related Research</i>	Influence of vertical soft tissue thickness on crestal bone changes around implants with platform switching: A comparative clinical study
Sicilia et al	2015	<i>Clinical Oral Implants Research</i>	Long-term stability of peri-implant tissues after bone or soft tissue augmentation. Effect of zirconia or titanium abutments on peri-implant soft tissues. Summary and consensus statements. The 4th EAO Consensus Conference 2015
Linkevičius et al	2015	<i>Clinical Oral Implants Research</i>	Radiological comparison of laser-microtextured and platform-switched implants in thin mucosal biotype
Linkevičius and Vaitelis	2015	<i>Clinical Oral Implants Research</i>	The effect of zirconia or titanium as abutment material on soft peri-implant tissues: A systematic review and meta-analysis
Puišys and Linkevičius	2015	<i>Clinical Oral Implants Research</i>	The influence of mucosal tissue thickening on crestal bone stability around bone-level implants. A prospective controlled clinical trial
Puišys et al	2015	<i>Clinical Oral Implants Research</i>	The use of acellular dermal matrix membrane for vertical soft tissue augmentation during submerged implant placement: A case series
Linkevičius	2017	<i>The International Journal of Periodontics and Restorative Dentistry</i>	The novel design of zirconium oxide-based screw-retained restorations, maximizing exposure of zirconia to soft peri-implant tissues: Clinical report after 3 years of follow-up
Linkevičius et al	2018	<i>Clinical Oral Implants Research</i>	Influence of titanium base, lithium disilicate restoration and vertical soft tissue thickness on bone stability around triangular-shaped implants: A prospective clinical trial
Linkevičius et al	2019	<i>The Journal of Prosthetic Dentistry</i>	Retention of zirconia copings over smooth and airborne-particle-abraded titanium bases with different resin cements

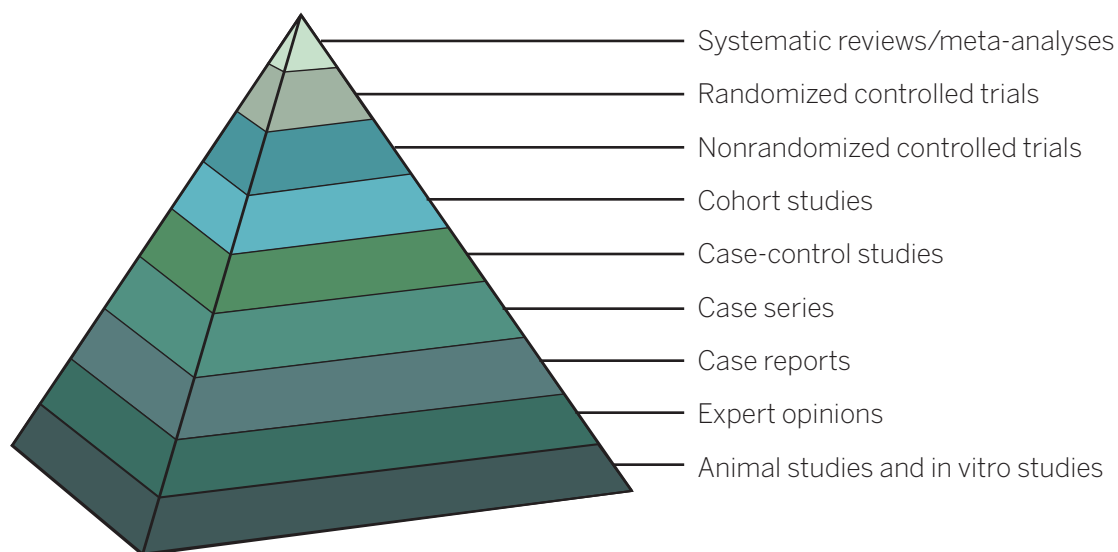
trials and soundly designed in vitro studies. Relying only on case reports can be quite dangerous. For example, in case reports, the use of rubber dam is suggested as a safe way to reduce cement remnants<sup>2</sup>; however, a controlled clinical study demonstrated completely opposite results.<sup>3</sup> In 2011, we created and published a simple and reliable technique for evaluation of cement remnants

after cementation.<sup>4</sup> This technique involves cementing a crown with an access hole in the occlusal surface, which is closed with composite to prevent cement from venting during the cementation process while allowing the restoration to be removed together with the abutment. Using this technique, we found that rubber dam is not able to prevent cement remnants (Fig 5).





**Fig 5** Rubber dam is not efficient in preventing cement remnants in a clinical situation. (a and b) The abutment and rubber dam are placed on the implant. (c) The crown is cemented. (d) The rubber dam and crown are removed. (e) Cement remains on the surface that is in contact with the peri-implant tissues. (f) There are no cement remnants in the peri-implant tissues.



**Fig 6** The hierarchy of evidence. It is important to note that expert opinions and case reports are only in eighth and seventh place, respectively.

This highlights the fact that case reports are subjective and resemble the opinions of the authors. This must be kept in mind when attending courses, listening to lectures, or reading

textbooks. The level of evidence is important, and it ranges from in vitro studies to randomized clinical trials (Fig 6). Animal and in vitro studies form the lowest spot in the ladder of evidence, and thus

they cannot be directly taken into the clinical world. Of course, some experiments can only be performed on animals, but we must not forget that, for example, dogs heal up to eight times faster than humans. Therefore, the results of studies in dogs should be regarded as best-case scenarios. However, we often see that animal studies are used to back clinical protocols, which is not correct. In vivo study should be used only as a guide before clinical trials are conducted. For example, consider the pharmaceutical industry. Would you use a medicine that was tested only on animals without clinical evaluation? The answer of course is no, and this is why the hierarchy of evidence should not be forgotten. Case reports also have their place in the hierarchy. A simple case report may be more important than a serious animal study, but we cannot base clinical strategy only on single clinical cases. Thus, it is important to balance the evidence, and case reports can serve as a first brick in building the scientific support of any concept.

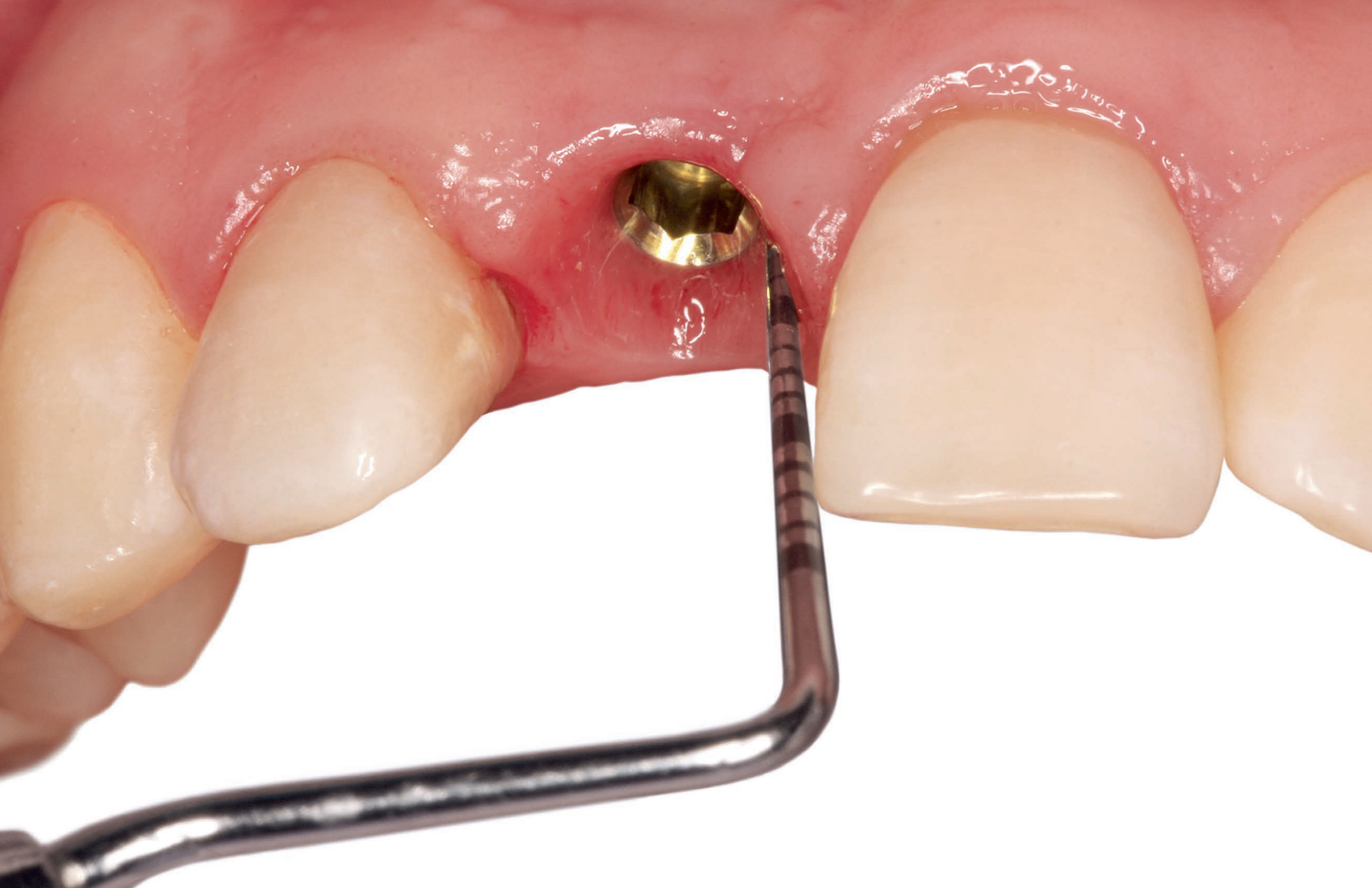In summary, the idea of this book is to balance scientific evidence and sound clinical logic to provide the best outcome for the patient.

## Structure of the Book

This book consists of two major parts: surgical and prosthetic. This structure simulates real clinical treatment, as implant placement is undertaken first, followed by prosthetic restoration. The surgical part is responsible for the development of crestal bone stability and involves various factors, such as vertical soft tissue thickness, implant placement level, position of the polished implant neck, and mode of implant-abutment connection. However, excellent surgical outcomes will not last long if the implant is poorly restored. Therefore, prosthetic concepts that will maintain crestal bone stability around implants are also presented.

## References

1. Linkevičius T, Puišys A, Steigmann M, Vindašiūtė E, Linkevičienė L. Influence of vertical soft tissue thickness on crestal bone changes around implants with platform switching: A comparative clinical study. *Clin Implant Dent Relat Res* 2015;17:1228–1236.
2. Seo CW, Seo JM. A technique for minimizing subgingival residual cement by using rubber dam for cement-retained implant crowns. *J Prosthet Dent* 2017;117:327–328.
3. Andrijauskas P, Alkimavičius J, Zukauskas S, Linkevičius T. Clinical effectiveness of rubber dam and gingival displacement cord with copy abutment on reducing residual cement for cement-retained implant crowns. *Clin Oral Implants Res* 2018;29(suppl 17):77.
4. Linkevičius T, Vindašiūtė E, Puišys A, Pečiulienė V. The influence of margin location on the amount of undetected cement excess after delivery of cement-retained implant restorations. *Clin Oral Implants Res* 2011;22:1379–1384.




# SECTION I

## SURGICAL CONCEPTS





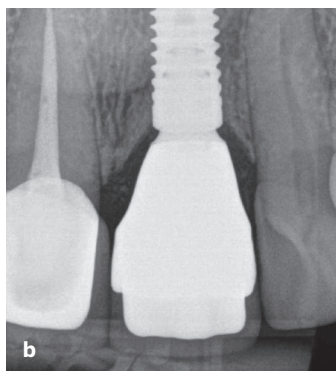
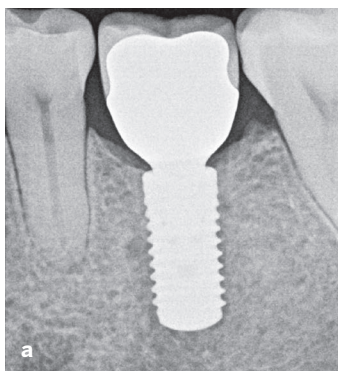


# SURGICAL FACTORS FOR ESTABLISHING CRESTAL BONE STABILITY

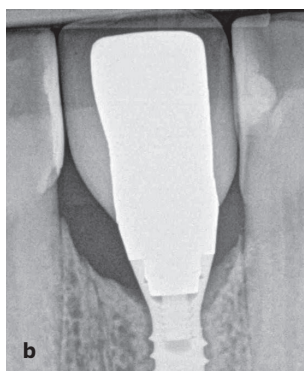
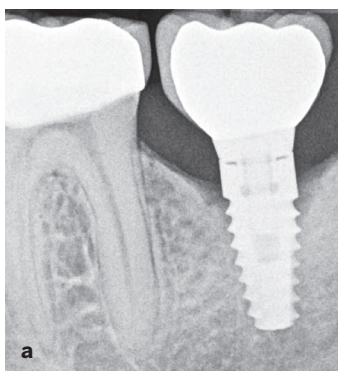
## Crestal Bone Loss

The importance of crestal bone stability around implants for the success and longevity of treatment cannot be overemphasized. The radiograph is the ultimate measurement of how well treatment has been performed. The radiographs in Fig 1-1 demonstrate an ideal treatment—the high quality of the treatment is clearly visible, and it must have been the result of good treatment decisions. It is well accepted by clinicians that stable bone with remodeling of less than 0.2 mm per year is one measure of successful long-term implant treatment, along with no bleeding on probing and a probing depth of no more than 5 to 7 mm.<sup>1</sup> On the other hand, a lack of stable bone may cause problems, leaving the clinician uncertain if the implant will remain stable for a longer period of time (Fig 1-2).

Crestal bone loss has accompanied implant treatment for so long that it has become the norm and has even been classified into different types. For example, *early crestal bone loss* is defined as bone resorption around the neck of the dental implant from placement to 1 year after loading. This definition is most likely based on the implant success criteria suggested by Albrektsson et al<sup>2</sup> in 1986, which state that 1.5 mm of bone loss within the



**Fig 1-1** (a and b) Examples of crestal bone stability.



**Fig 1-2** (a and b) Examples of crestal bone loss.

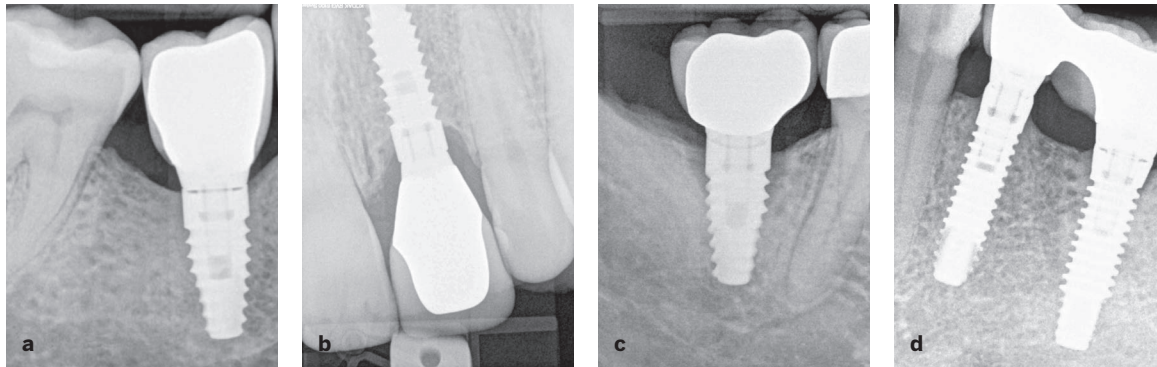
first year of loading can be considered a success if later bone loss does not exceed 0.2 mm annually. This concept was developed from observations of original Brånemark implants; however, implants used in contemporary dentistry have superior designs and surfaces that result in more success and bone stability. Therefore, some recent studies have questioned the accepted success criteria, stating that it is possible for implants to have lower amounts of bone loss after 1 year of function.<sup>3,4</sup> It was reported that implants with microthreads in the neck region and a conical implant-abutment interface may be expected to have only 0.33 to 0.56 mm of bone loss within 12 months of loading.

In the dental literature, early crestal bone loss is sometimes described as “saucer-shaped,” “crater-like,” or “ditch-like,” as these descriptions indicate the typical pattern of bone loss seen on radiographs. This type of loss has historically been considered a natural and unavoidable result of biologic remodeling and a difference in bone stiffness. Occlusal trauma was suggested as a factor; however, if occlusal functioning causes constant

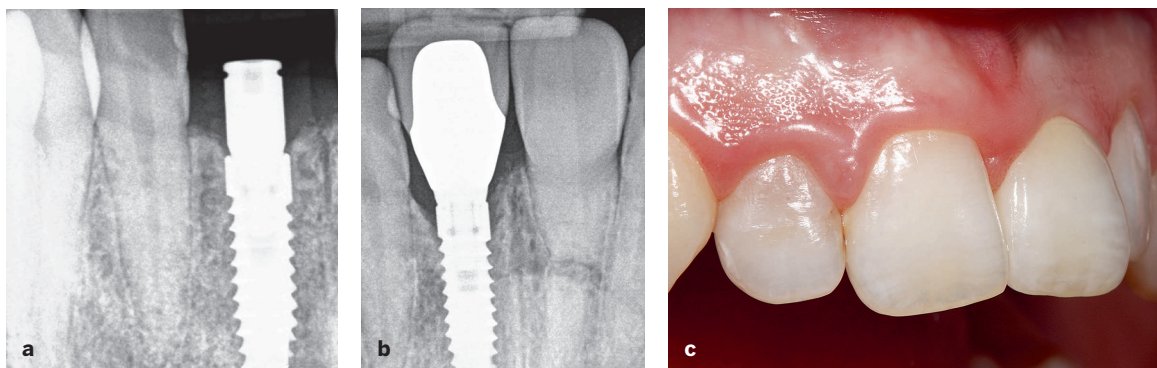
overload at the implant neck area, it is unclear why bone loss ceases after some time rather than continuing until complete implant failure. To explain this phenomenon, it has been suggested that bone is less dense and more sensitive to stresses in the beginning of prosthetic loading, causing overloading and therefore resorption; however, within the first year of loading, bone matures and becomes denser, so the occlusal forces that initially cause crestal bone loss are not great enough to evoke further bone resorption. And yet, despite constant innovation and development of new effective techniques and materials, clinicians still face the problem of bone loss.

It is the author’s belief that old standards in implant dentistry, where 1 mm of bone loss is thought to be normal, should no longer be considered valid. In fact, bone can have different reactions to the presence of implants, such as the following (Fig 1-3):

- Zero bone loss
- Stable remodeling
- Progressive bone loss



**Fig 1-3** Different reactions of crestal bone level to dental implants. (a) Zero bone loss. (b) Stable remodeling. (c) Progressive bone loss. (d) Bone growth.



**Fig 1-4** Example of stable crestal bone remodeling. (a) Bone level before development of biologic width. (b) Stable bone position exposing the implant neck without threat to implant survival. (c) In this case, there were no esthetic consequences of the stable bone remodeling.

- Bone demineralization and remineralization
- Corticalization
- Bone growth

## Zero bone loss

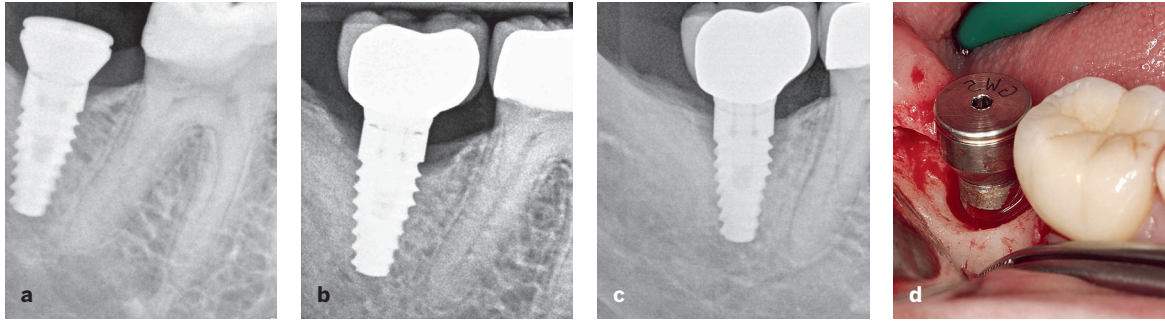
*Zero bone loss* (a term introduced by the author), or crestal bone stability, is when the bone has not receded or been lost for any reason whatsoever. This term was chosen over an equivalent phrase like “no bone loss” as a challenge for clinicians to meet.

## Stable remodeling

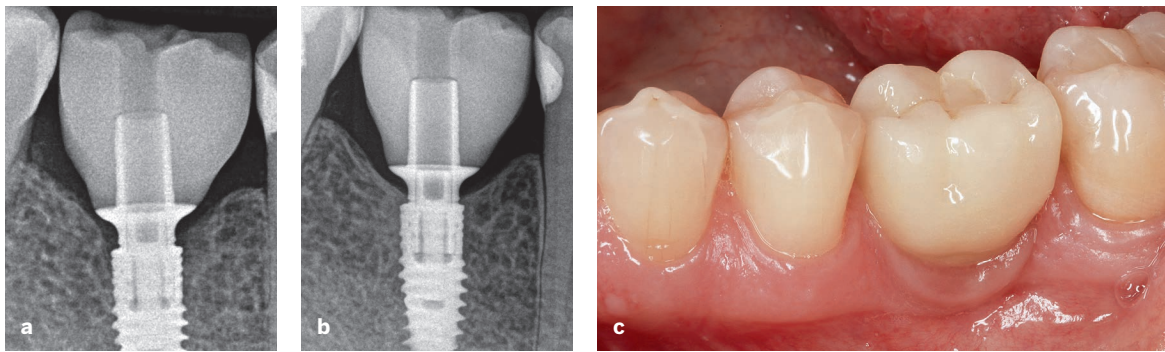
*Stable remodeling* refers to the presence of some bone loss that stops after some time and does not proceed further. It can be caused by biologic or

mechanical factors. These implants are generally stable, and bone loss does not cause a threat to implant function (Fig 1-4). However, it would still be better to avoid this level if possible, especially considering that stable bone loss can be steady for some time, resulting in an anaerobic environment that is difficult to manage. If a patient suddenly has a periodontal infection or reduced oral hygiene capabilities, an implant with stable remodeling is more susceptible to further bone resorption than one with zero bone loss. In other words, bone around implants with stable remodeling is more prone to resorb unexpectedly in the future. This resorption cannot be restricted without intervention and therefore poses a threat to the overall outcome of treatment. When zero bone loss concepts are implemented, the chance to develop peri-implantitis is the lowest.





**Fig 1-5** (a) Bone level after implant placement. (b) Bone position just after delivery of prosthesis. (c) At 1-year follow-up, half of the implant is no longer in the bone. (d) A crater has formed in the bone, so the implant must be removed.



**Fig 1-6** Remineralization of crestal bone around implants (V3, MIS). (a) Delivery day. (b and c) After 1 year.

## Progressive bone loss

When stable bone remodeling becomes ongoing bone loss, it is referred to as *progressive bone loss*, a dangerous crestal bone condition that affects the functional and esthetic outcomes of treatment. It is impossible to predict whether remodeling will stop or continue, and if bone loss is not stopped, it can lead to extensive problems, including peri-implantitis or even loss of the implant (Fig 1-5).

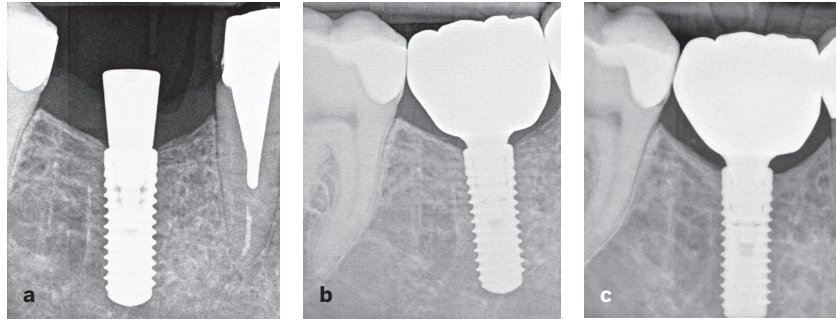
## Bone demineralization and remineralization

Crestal bone can behave differently at various levels of healing and development, and in some situations, bone remineralization or demineralization can occur (Fig 1-6). Bone can become more or less mineralized over time as minerals enter or leave

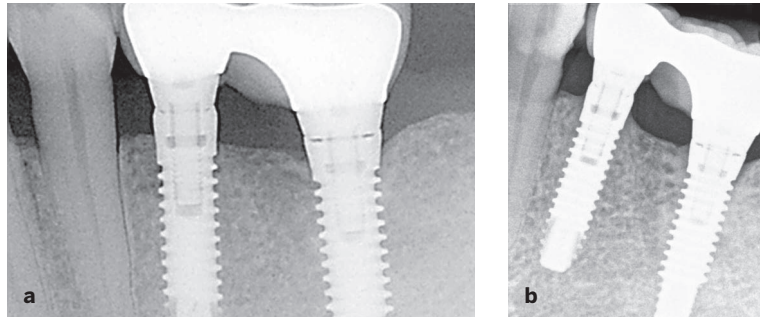
the organic matrix of the bone. It is unknown exactly why this occurs. Therefore, crestal bone loss is not always true resorption of the bone tissue; sometimes it can be the demineralized organic matrix presenting as bone loss. The tool used to detect bone loss is a two-dimensional radiograph, on which demineralized bone appears as bone resorption. Cases of occlusal trauma around teeth with widening of the periodontal ligament are similar because they might look like bone loss at the crest. However, when the trauma is eliminated, periodontal ligament space is reduced to its normal dimensions.

This might be compared with remineralization of alveolar bone around the tooth, as demonstrated by Rosling et al,<sup>5</sup> who showed that bone regeneration occurs in infrabony pockets in patients who maintain an optimal standard of oral hygiene. When infection and irritants are removed, the organic bone matrix remineralizes. This may

**Fig 1-7** Corticalization process visible radiographically. (a) Normal cortical plate after implant placement. (b) The plate is getting thicker medially after loading. (c) Corticalization and thickening of the plate 3 years after loading.



**Fig 1-8** (a and b) Over time, bone has continued to grow around the crest of the implant. Although exactly what happens during this process is unknown, it is possible to observe vertical extension of the bone around the premolar implant mesiodistally and around the molar implant mesially.



happen around non-platform-switched implants as well. Clinical observations suggest that when the prosthetic phase of the treatment is over, and tissues are left undisturbed, a favorable environment for bone remineralization is created.<sup>6</sup>

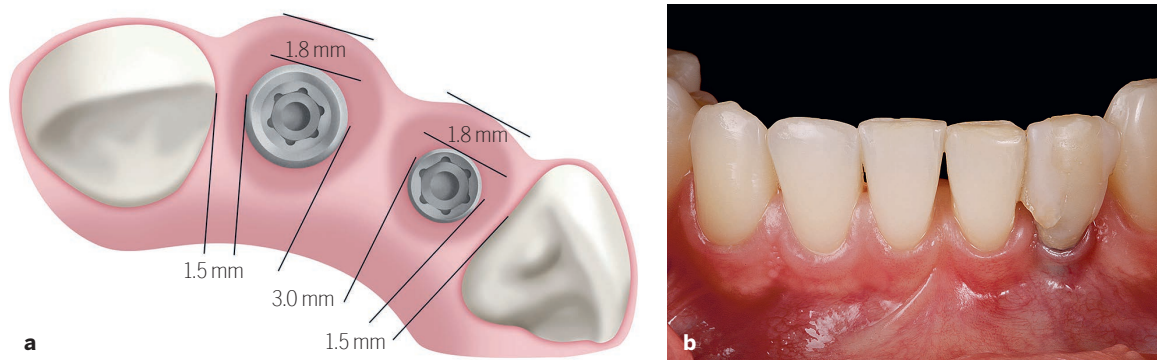
## Corticalization

*Corticalization* is a process that occurs when the cortical plate of alveolar bone becomes more dense, or mineralized. On the radiographs in Fig 1-7, it can be observed that the cortical plate becomes more intensely white and increases in height over time after loading. The reason for this is not clearly understood, but one proposed explanation is Frost's law, which states that mild overloading of the bone results in an increase in its mass. This process is similar to vertical bone growth, but it manifests as increasing and intensifying zones of mineralization cortically. It is also present when the cortex of the alveolar ridge is removed and an implant is placed into purely trabecular bone. This process does not pose any threat to implant integration; some say it is even

beneficial because trabecular bone has more blood supply, and as the outer part of trabecular bone becomes mineralized, the desired corticalization results.

## Bone growth

To date, there are no clinical studies demonstrating a predictable process for achieving bone growth after implant placement and restoration delivery. However, it has been hypothesized that the constant loading of the implant stimulates the growth of the bone, as the force is transmitted to the bone from the implant. The implant is mobile in the bone up to 10  $\mu\text{m}$ , so micromovement stimulates the bone, possibly causing it to grow. Vertical growth could be explained by the ossification of the periosteum or connective tissue, which lays directly on the bone surface (Fig 1-8). The processes of bone remineralization and bone growth are encouraging because they indicate that some improvement can occur over time, even in cases of crestal bone loss.



**Fig 1-9** (a) Horizontal bone loss may have a vertical component if the bone width is thin, which results in vestibular tissue collapse. (b) Note the grayish appearance of the soft tissues around the restoration, indicating crestal bone loss and thinner tissues.

## Importance of Stable Bone

Though some clinicians may find the importance of bone stability to be obvious, the reasoning for this is worth reviewing: Crestal bone stability is important because it guarantees implant function in the first place. Therefore, the goal should always be prevention of bone loss. As mentioned previously, peri-implant crestal bone stability reflects on the treatment skills and choices of the clinicians involved in both the placement and the restoration of the implants.

The literature reveals that early crestal bone loss usually does not threaten osseointegration of the implant; however, in some specific cases, such as those with thin peri-implant cortical bone, short implants, or high esthetic value, the presence or absence of crestal bone could significantly affect the survival and success of the implant.<sup>7</sup> Crestal bone plays a major role in primary (ie, short-term) and long-term implant stability. Primary stability is key to osseointegration, as it is well described and proved that primary stability ensures transition to secondary stability, which is characterized by biologic interlocking of the bone and the implant surface.<sup>8</sup> When the implant is restored and brought into function, presence of adequate crestal bone is also one of the major factors in securing long-term success. A number of finite element analysis studies have shown that when axial and lateral physiologic forces are applied to the

implant, high peak stresses are generated in cortical bone.<sup>9-12</sup>

Although clinicians should strive for bone stability in all cases, there are two major situations that require bone levels to be as stable as possible: (1) implants in the esthetic zone and (2) the use of short implants.

## Implants in the esthetic zone

The stability of the peri-implant mucosal level is largely dependent on the height of the underlying bone. The consequence of marginal peri-implant mucosal migration as a result of marginal bone loss has a major influence on the esthetics of the restoration, particularly in the anterior region. Peri-implant mucosal recession, which may follow crestal bone loss, results in crown margin exposure, soft tissue recession, and loss of the papilla.<sup>13</sup> This depends on the width of bone because as crestal bone resorbs horizontally, vertical height of bone may also be lost (Fig 1-9).

When there is vertical crestal bone resorption, the bone changes form a circular pattern around the implant. This results in facial bone changes during the process of bone remodeling. When there is greater bone width, a so-called crater forms around the implant, but the outer facial wall is unaffected; however, if the bone is thin, facial bone is lost as well.