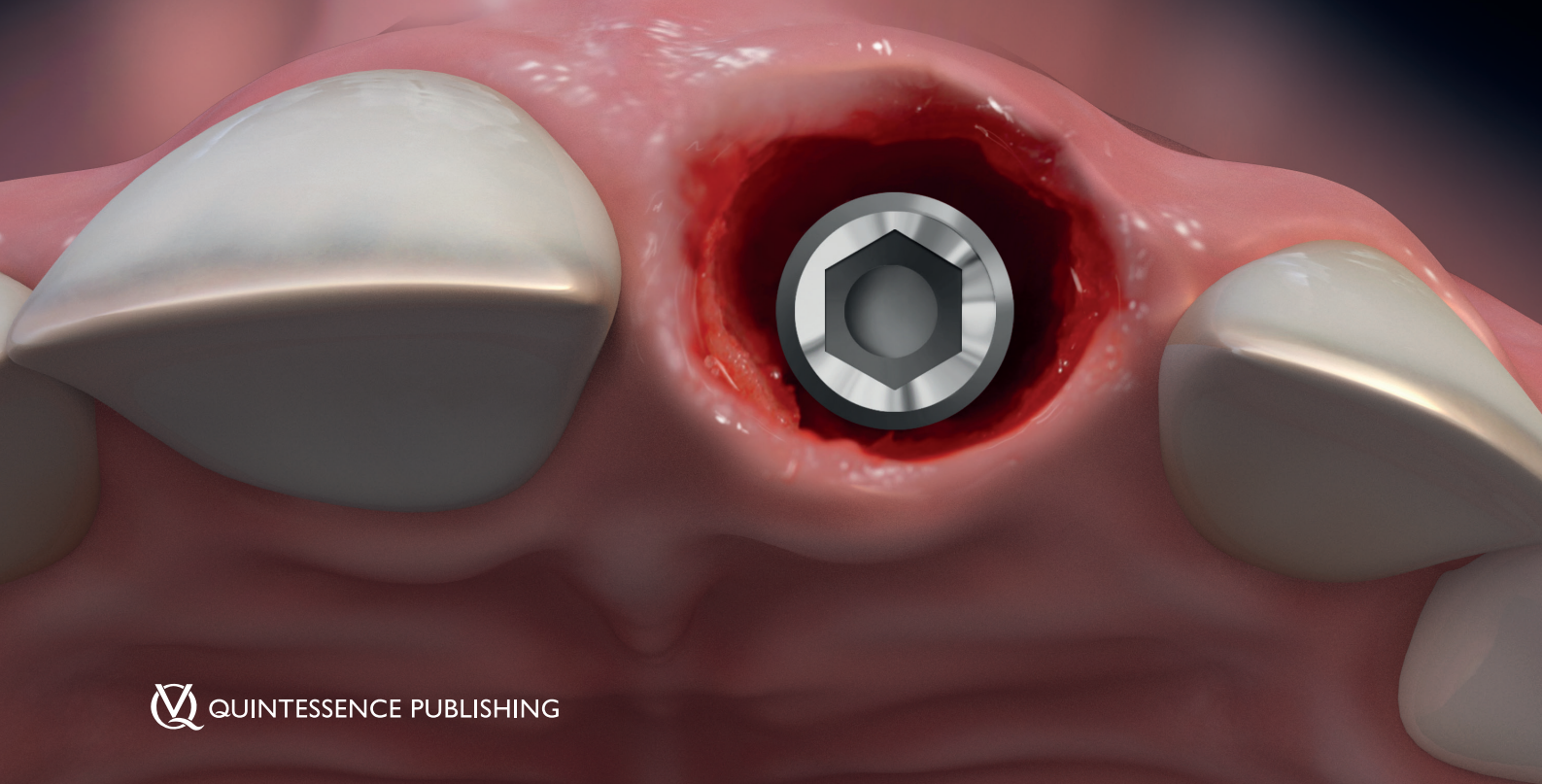


The Single-Tooth Implant

Dennis P. Tarnow, DDS
Stephen J. Chu, DMD, MSD, CDT

A Minimally Invasive Approach
for Anterior and Posterior
Extraction Sockets



The Single-Tooth Implant

A Minimally Invasive Approach for Anterior and Posterior Extraction Sockets

The Single-Tooth Implant

A Minimally Invasive Approach
for Anterior and Posterior
Extraction Sockets

Dennis P. Tarnow, DDS

Clinical Professor and Director of Implant Education
Department of Periodontology
Columbia University College of Dental Medicine

Private Practice
New York, New York

Stephen J. Chu, DMD, MSD, CDT

Adjunct Clinical Professor
Ashman Department of Periodontology & Implant Dentistry
Department of Prosthodontics
New York University College of Dentistry

Private Practice
New York, New York



QUINTESSENCE PUBLISHING

Berlin, Barcelona, Chicago, Istanbul, London, Mexico City, Milan,
Moscow, Paris, Prague, São Paulo, Seoul, Tokyo, Warsaw

Library of Congress Control Number:2019943782



©2020 Quintessence Publishing Co, Inc

Quintessence Publishing Co Inc
411 N Raddant Rd
Batavia, IL 60510
www.quintpub.com

5 4 3 2 1

All rights reserved. This book or any part thereof may not be reproduced, stored in a retrieval system, or transmitted in any form or by any means, electronic, mechanical, photocopying, or otherwise, without prior written permission of the publisher.

Editor: Leah Huffman
Design: Sue Zubek
Production: Angelina Schmelter

Printed in China

Contents

Foreword viii

Preface ix

CHAPTER 1 History and Rationale for Anterior and Posterior Single-Tooth Implants 1

Immediate Versus Delayed Tooth Replacement Therapy

Clinical Example

Challenges with Immediate Implant Placement

Classification of Extraction Sockets

Diagnostic Aids for Socket Management: Radiographic and Clinical Examination

CBCT

Probes

CHAPTER 2 Management of Type 1 Extraction Sockets 19

Flapped Versus Flapless Tooth Extraction: Evidence-Based Rationale

Blood supply to the labial plate

Labial contour and ridge dimensional change

Tooth Extraction Techniques with Specific Instrumentation

Single-rooted anterior teeth

Multirrooted posterior teeth

3D Spatial Implant Placement Within the Anterior Extraction Socket

The influence of implant position on restorative emergence profile

Implant placement

Implant angulation

Implant depth

Horizontal Soft Tissue Thickness

Connective tissue grafts around implants and edentulous ridges

Periodontal phenotype

Gap Distance and Wound Healing

Primary flap closure versus secondary-intention wound healing

Case example and histologic evidence

Hard tissue grafting of the gap

Bone Thickness and Ridge Dimensional Change

Peri-implant Soft Tissue Thickness

Tissue discoloration around implants

Layperson's perception threshold of faciopalatal ridge collapse

Dual-Zone Socket Management

Bone graft materials

Bone graft material for dual-zone therapy

Prosthetic socket sealing

iShell technique

Sulcular Bleeding at First Disconnection of an Implant Healing Abutment

Cement- Versus Screw-Retained Provisional and Definitive Restorations

Abutment Selection: Materials and Color Considerations

Management of Teeth with Periapical Lesions, Fistulae, and Ankylosis

Periapical lesions and fistulae

Ankylosed teeth

Implant Design for Immediate Placement

Tapered vs cylindrical implants, thread design, and thread pitch

Platform switching

One abutment, one time

Coaxial versus straight implants

Inverted body-shift design implant

Wide-body versus regular-width implants

CHAPTER 3 Management of Type 2 Extraction Sockets 77

Implants Placed Immediately into Type 2 Extraction Sockets

Clinical example

Delayed Implant Placement

Membranes for socket preservation

Ice cream cone technique

Delayed implant placement with immediate provisional restoration

Flap Design for Delayed Implant Placement After Ridge Healing

Punch technique

Flap technique

Soft tissue sculpting with the provisional restoration

CHAPTER 4 Management of Type 3 Extraction Sockets 101

Treatment of 3 mm of Midfacial Recession

Treatment of 1 mm of Midfacial Recession with Absence of Labial Bone Plate

CHAPTER 5 Clinical Management of Posterior Teeth 117

Tooth Extraction for Multirooted Teeth

Implant Placement into Molar Extraction Sockets

Type A

Type B

Type C

Alternative Immediate Molar Implant Placement Strategies

Clinical Example

Delayed Protocol for Molar Teeth

CHAPTER 6 Important Considerations in Implant Dentistry 131

Cementation Methods

Impression-Making Techniques

Complications

Occlusal overloading

Breakage or delamination of the provisional restoration from temporary cylinders

CHAPTER 7 Clinical Case Appendix 141

Type 1

Case 1: Horizontal fracture of maxillary central incisor

Case 2: Large internal resorption lesion

Case 3: Internal resorption lesion at maxillary central incisor

Case 4: Vertical crown fracture of maxillary central incisor

Case 5: High smile line

Case 6: High smile line and chronic fistula

Type 2

Case 7: Loss of labial plate

Case 8: Periapical lesion and tooth fracture with necrosis

Type 3

Case 9: Loss of labial plate at maxillary central incisor

Molars

Case 10: External resorption lesion of maxillary first molar

Case 11: Vertical root fracture of mandibular first molar

Index 227

Foreword

Education is the key to changing lives. It is fundamental to how practitioners treatment plan with the understanding of biology and eventually improve patient outcomes. Over the past three decades, I have had the opportunity and pleasure to work closely with Drs Dennis P. Tarnow and Stephen J. Chu in the arena of both domestic and international continuing dental education. Dennis and Steve are exceptional academic educators, prolific researchers, and caring private practitioners. Both are inspirational teachers and lifelong learners, always questioning and exploring the frontiers of dental knowledge with fresh insights and innovative approaches to everyday clinical dentistry. Exceptional teachers are hard to find, but these individuals are always rising to the challenge of turning on the lights in our darkness. Both are aware that only biologic principles dictate final clinical outcomes. Through their knowledge and expertise, they guide each of us in our search for the elusive truths in implant dentistry.

Based on their clinical experiences and research findings, this textbook is comprehensive and engaging. Written by clinicians for clinicians, the flow and language are clear and to the point. The chapters progressively address diagnosis as well as simple to more complex

single-tooth implant scenarios. The book begins with a discussion of the history and rationale for anterior and posterior single-tooth implants, and then it walks the reader through the three types of sockets—type 1, type 2, and type 3—and their various indications and limitations. An entire chapter is devoted to clinical management of posterior teeth, followed by a chapter on cementation and impression-making techniques and complications. The final chapter is a clinical case appendix detailing 11 cases of single-tooth replacement in all types of sockets previously described. What a treasure trove!

This fresh and insightful publication by two world-class masters in clinical dentistry who have worked together for decades will inspire the reader to keep learning and growing in the ever-changing world of dental knowledge. Learn from the best, increase your clinical predictability, enhance your problem-solving capabilities, and watch your practice grow with new knowledge and confidence. Let the lantern of learning keep shining.

H. Kendall Beacham, MBA
Assistant Dean, Linhart Continuing
Education Program
New York University College of Dentistry

Preface

Our love and passion for dentistry as well as a desire to share what we have learned over the years as clinicians, teachers, and researchers led us to write this modern-day textbook on the single-tooth implant. The replacement of the single tooth with a dental implant is one of the most common clinical situations practitioners face on a daily basis.

During our respective careers and close collaboration over the last 15 years, we have completely modified our approach to the management of hopeless teeth, especially in the esthetic zone. In the past, sockets were left untouched after tooth extraction for months before attending to the residual ridge. Today we perform “one surgery, one time” whenever possible, which is quite often and a huge benefit to both the patient and clinician alike. We have documented the

periodontal and restorative interrelationships in treatment with great success alongside new and innovative techniques that enhanced esthetic outcomes in less treatment time for our patients.

During the compilation of this book, the reader was always foremost in our minds, with the hope of providing not only a better understanding of diagnosis and treatment with evidence-based concepts but also biologic principles of wound healing, thus making patient care faster, easier, simpler, more predictable, and, in many cases, less costly.

We hope you enjoy seeing the results of our professional journey in this challenging field and enjoy reading this textbook as much as we enjoyed composing it. We wish you much success in the treatment endeavors with your patients!

With contributions from

Guido O. Sarnachiaro, DDS

**Clinical Assistant Professor
Department of Prosthodontics
New York University College of Dentistry**

**Private Practice
New York, New York**

Richard B. Smith, DDS

**Private Practice
New York, New York**

Acknowledgment

Special thanks to Adam J. Mieszko, CDT, for all the laboratory work presented throughout this book.



IN THIS CHAPTER:

- Immediate Versus Delayed Tooth Replacement Therapy
- Clinical Example
- Challenges with Immediate Implant Placement
- Classification of Extraction Sockets
- Diagnostic Aids for Socket Management: Radiographic and Clinical Examination

History and Rationale for Anterior and Posterior Single-Tooth Implants

The single-tooth implant restoration comprises roughly one-half of all the implant case types that present daily in a clinical practice, and in the authors' experience, many are in the esthetic zone. This section discusses some of the current concepts, science, and knowledge associated with immediate implant placement and provisional restoration in anterior postextraction sockets, better known as *immediate tooth replacement therapy* because both the root of the tooth and the clinical crown are being replaced simultaneously.

Some common questions that arise when a tooth is removed and an implant is placed into a fresh extraction socket include the following:

- What happens when a tooth is extracted?
- What kind of hard and soft tissue dimensional changes take place as a result?
- Are there differences in wound healing of anterior versus posterior extraction sockets?
- Should flap elevation be employed to remove the root remnant?
- Should primary flap closure be used, or should the socket be allowed to heal by secondary wound intention?
- What graft, if any, should be used?

- Should a connective tissue graft be placed in conjunction with the implant?
- What is the proper 3D spatial position of the implant within the extraction socket?
- Does the graft alter the wound healing process of the extraction socket?
- Does it make a difference if there is a residual gap after implant placement?
- Should a provisional restoration or custom healing abutment be fabricated in conjunction with the implant, or is it better just to place a stock healing abutment? Which would be better in regard to implant survival, osseointegration, and esthetic success?

These are just some of the questions that arise when immediate placement of implants into postextraction sockets is discussed. All of these topics remain controversial, and every practitioner has his or her own solutions, but how reliable are the results? This book seeks to answer these questions and to provide objective and concrete information to help clinicians, both specialists and general practitioners alike, place single-tooth implants and restore them with consistent periodontal, restorative, and esthetic outcomes in various clinical situations.

Immediate Versus Delayed Tooth Replacement Therapy

The survival rates for immediate implant placement are equal to, if not slightly higher than, those for delayed implant placement.¹ The literature seems to support this.²⁻⁹ While the delayed protocol has survival rates higher than 90%, the immediate protocol boasts survival rates of 95%.⁵ Among anterior teeth alone, the survival rate increases to 97%.^{4,5} So it stands to reason: If the placement of an implant directly into the extraction socket has no bearing on that socket's ability to heal, why not do it? After all, the socket is genetically engineered to heal whether or not a sterile titanium screw, which is biologically acceptable and compatible, is placed.

The main advantage of immediate tooth replacement therapy is that it condenses treatment procedures into fewer patient appointments, thereby reducing overall treatment time and increasing patient comfort while preserving the natural shape of the surrounding hard and soft tissues (Table 1). Most of the procedures such as tooth extraction, implant placement, socket grafting, and provisional restoration are delivered at the first treatment appointment, so more time should be appropriately allotted. With this approach, the clinician has the ability and opportunity to preserve hard and soft tissues at the time of tooth extraction, especially for a single tooth and maybe even multiple adjacent implants. This preservation concept is critical for esthetics, which is a major advantage with today's esthetically demanding and knowledgeable patients.¹⁰

Conversely, delayed implant placement affords the clinician the opportunity to perform all site development prior to implant placement, provided that the clinical situation is amenable to augmentation and correction.¹¹⁻¹³ However, this protocol requires more treatment time: First the tooth is extracted, then the socket must heal for several months before implant placement with contour grafting is performed either as a single- or two-stage procedure. Once the implant has integrated, the implant is surgically exposed (two-stage procedure), and a flat profile healing abutment can be placed. The patient must return for nonsurgical soft tissue sculpting after soft tissue healing around the healing abutment, which is subsequently followed by another appointment for final impression making and definitive restoration¹⁴ (Table 2). This prolonged course of treatment is not ideal for the patient or the clinician, especially if all of the anatomy is present prior to tooth extraction.¹⁵ In addition, once the proximal contacts are eliminated following tooth removal, both interdental papillae shrink, and they are not always easily retrieved, especially in a thin scalloped phenotype. In 1997, Jemt showed that 1.5 years after implant placement, the mesial papilla filled completely only 68% of the time in 25 single-tooth implant sites (21 anterior sites), while the distal papilla had complete fill less than half the time (48%).¹⁶ Furthermore, papillae may not re-form to their pretreatment height of roughly 40% of the tooth length from the gingival zenith position. Immediate tooth replacement therapy provides a better opportunity for this re-formation.^{17,18}

While the delayed approach allows for soft tissue maturation and site development,

TABLE 1 Immediate implant protocol

Appointment #	Surgical intervention	Healing time (weeks)
1	Tooth extraction, implant placement, socket grafting, provisional restoration or custom healing abutment	12–24
2	Impression making	None required
3	Delivery of definitive restoration	None required

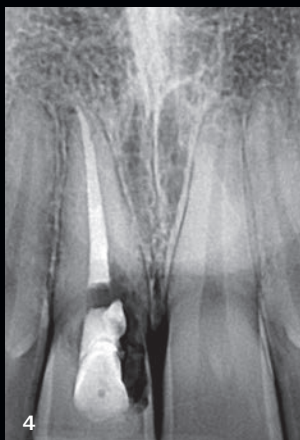
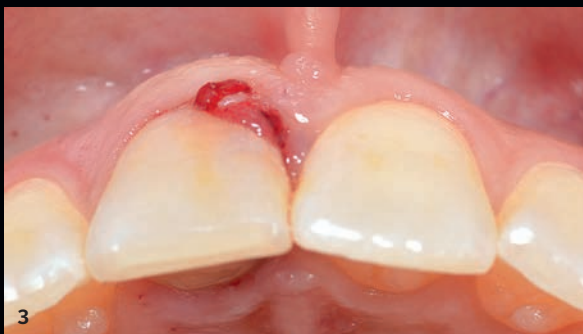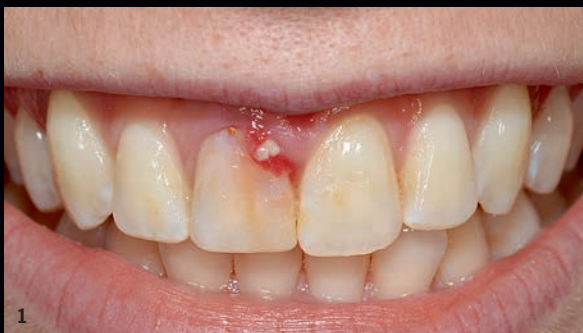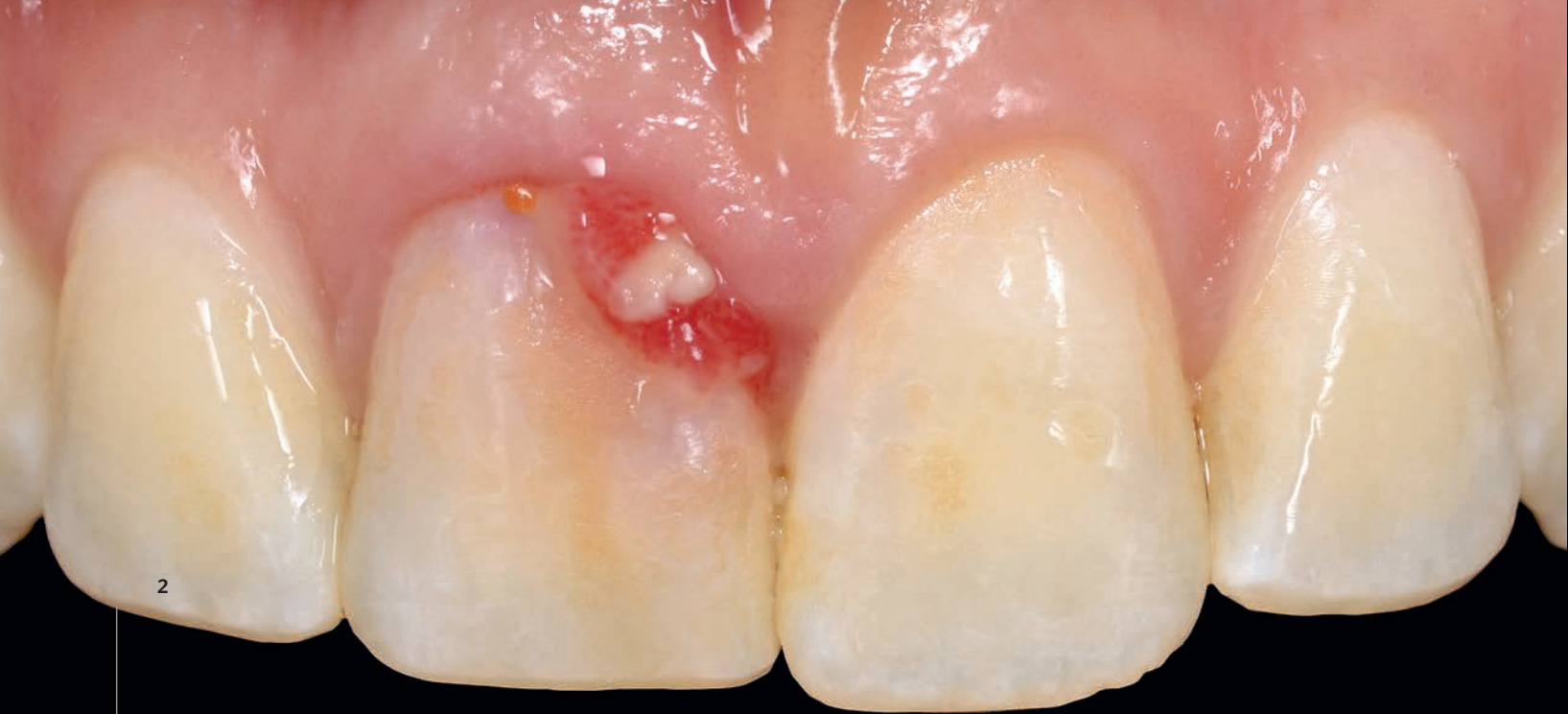TABLE 2 Delayed implant protocol

Appointment #	Surgical intervention	Healing time (weeks)
1	Tooth extraction	6–12
2	Ridge augmentation*	12–24
3	Early implant placement*	12–24
4	Stage 2 uncovering	2–4
5	Nonsurgical soft tissue sculpting	2–4
6	Impression making	None required
7	Delivery of definitive restoration	None required

*Note that procedures #2 and #3 can be combined in some instances.

immediate tooth replacement therapy offers the distinct advantage that the existing tooth extraction site and socket become the osteotomy to help guide the placement of the implant. In a fresh extraction socket, the mucosal tissue is exposed from the trauma, so the provisional restoration or custom healing abutment should be well adapted to the contours of the extraction socket walls, maintain the peri-implant tissue in the preextraction state, and be cleaned or disinfected (ie, steam cleaning) prior to insertion

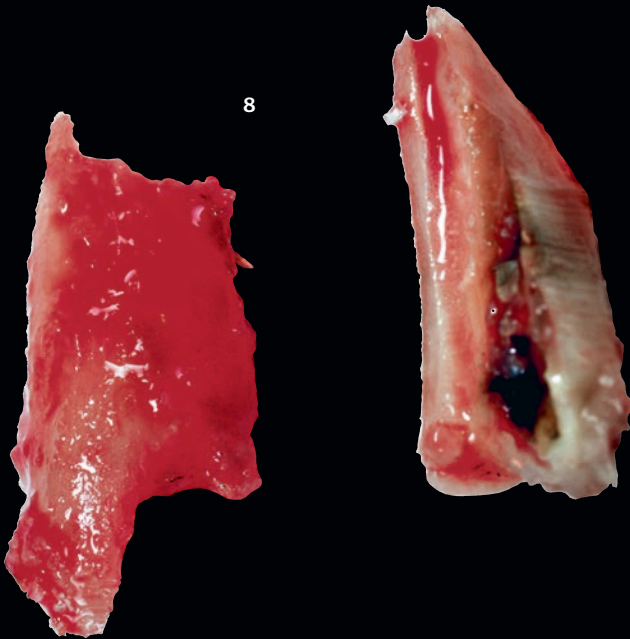
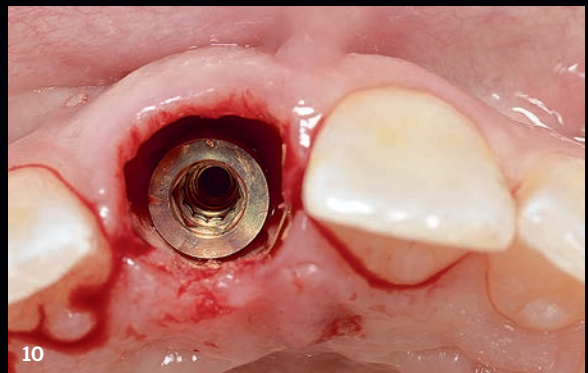
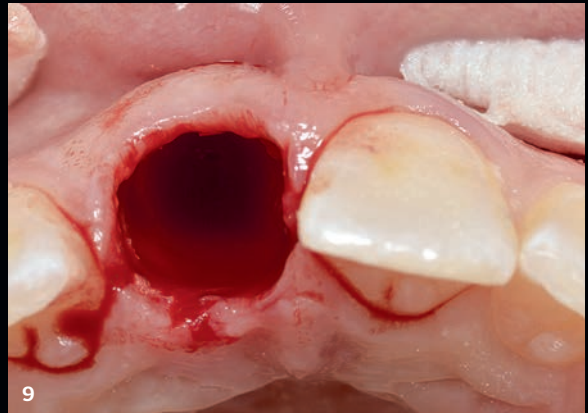
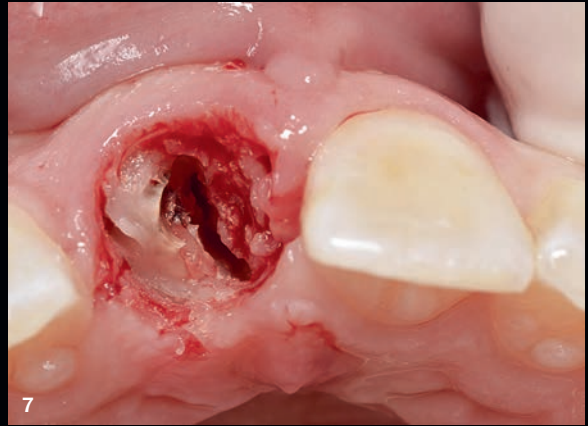
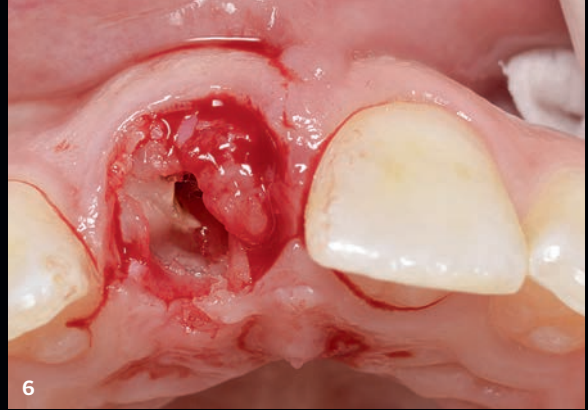
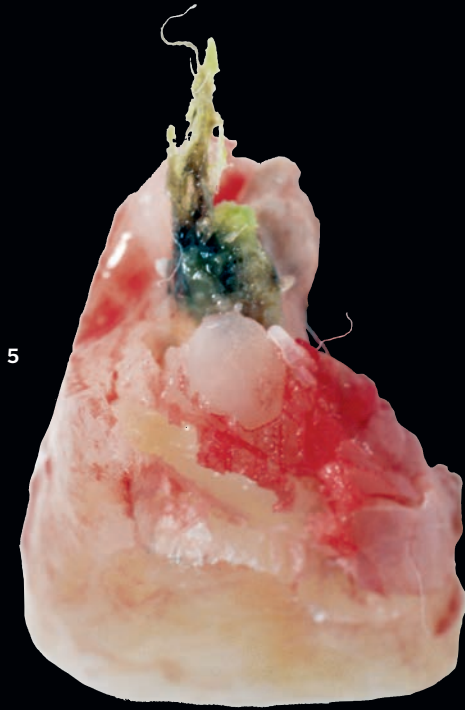
regardless of the material used. The beauty of immediate provisional restoration is that the soft tissue architecture can be captured and preserved immediately at the time of tooth removal. The goal of therapy is to preserve, maintain, and protect the existing tissues rather than try to recreate what is lost. Proper 3D implant placement, platform switching, and correct soft tissue support with a provisional restoration can result in a predictable restorative and esthetic outcome.

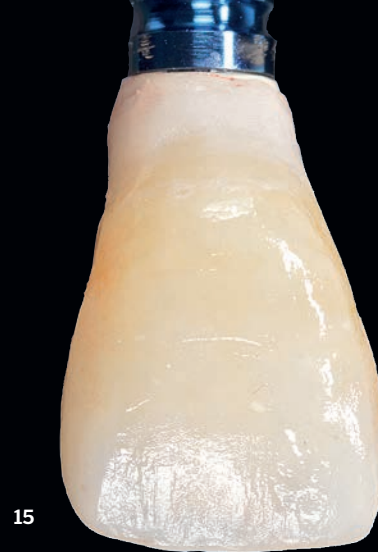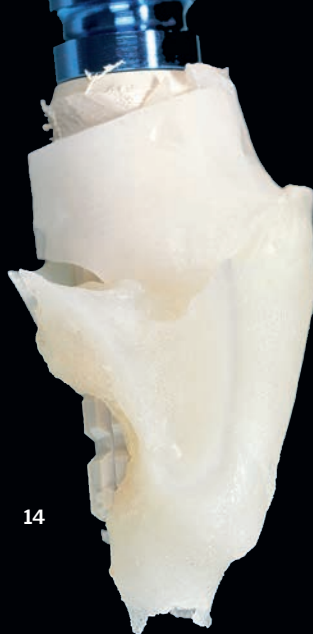
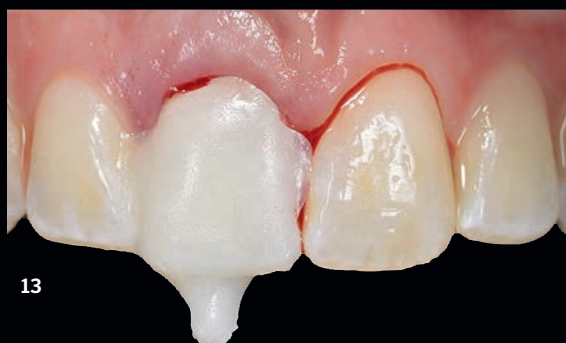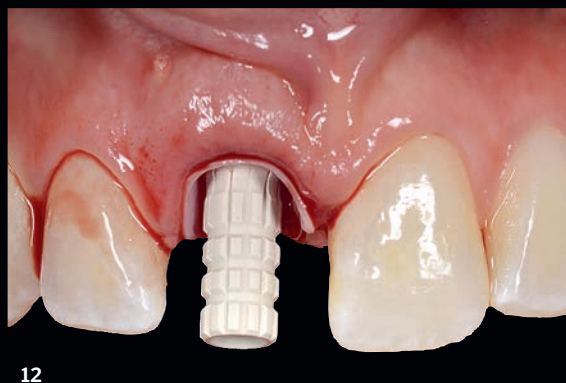
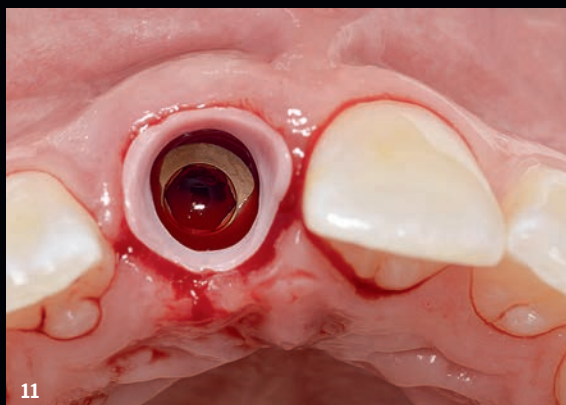


Clinical Example

A 21-year-old woman with a high smile line presented with advanced external resorption of the maxillary right central incisor at the mesiofacial aspect (Figs 1 to 3). The periapical radiograph showed a cavernous lesion that undermined the structural integrity of the tooth (Fig 4). The soft tissue margin of the right central incisor was slightly more coronal than that of the left central incisor, which is a benefit in treatment if recession should occur (see Fig 2). During tooth extraction, the weak coronal tooth structure fractured with the slightest force (Fig 5). The ingrowth of granulomatous tissue is seen within the mesiofacial socket wall (Fig 6). Sharp dissection with a no. 15c scalpel blade was used to remove the affected tissue, and a fine tapered surgical diamond bur (Brasseler #859 long shank) was used to section the root facio palatally (Fig 7). The residual roots were luxated and removed without damaging the extraction socket (Fig 8; see chapter 2 for tooth extraction techniques).

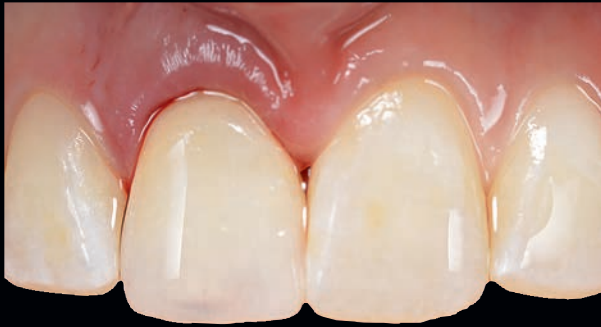The socket was thoroughly debrided (Fig 9), and a 5.0-mm-diameter implant (Zimmer Biomet) was placed to the palatal aspect of the socket to allow platform switching (Fig 10). A preformed gingival shell former (iShell, BioHorizons/Vulcan Custom Dental) was used to capture the preextraction state of the



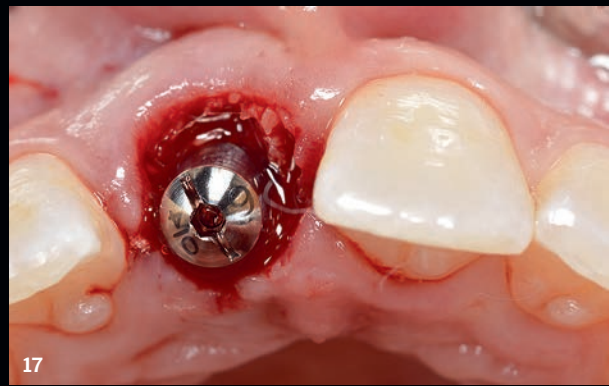


peri-implant tissues (Figs 11 and 12). The shell was joined to a screw-retained PEEK (poly-etheretherketone) temporary cylinder with acrylic resin (Super-T, American Consolidated) with the accompanying clinical crown (Fig 13). After autocuring of the acrylic resin, it was removed intraorally, contoured, and custom colored (OPTIGLAZE Color, GC America) (Figs 14 and 15) to match the contralateral central incisor. Note how the preformed gingival shell former captures the shape of the subgingival contours of the extraction socket without voids (see Fig 14), which would normally occur due to the formation of a clot as well peri-implant soft tissue collapse.

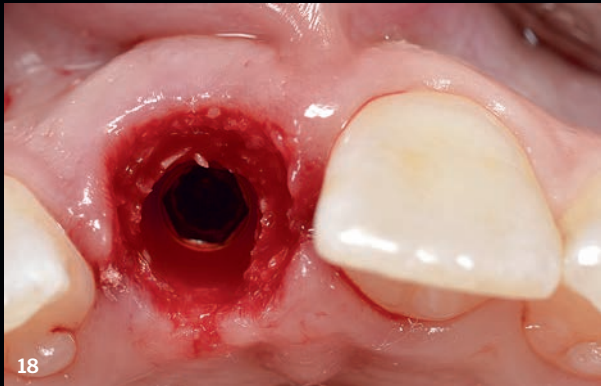
The provisional crown restoration was tried back onto the implant to verify the shade, contour, and nonocclusal contact in maximum intercuspal position (MIP) and lateral excursive movements (Fig 16). The provisional crown was subsequently removed, and a flat-profile healing abutment with platform switching was placed to allow a small-particle, mineralized cancellous allograft to be packed into the labial gap (Fig 17). The healing abutment was then removed, and the provisional crown was resealed to contain and protect the graft material during the healing phase of therapy (Figs 18 and 19). After 1 week of uneventful healing, the patient



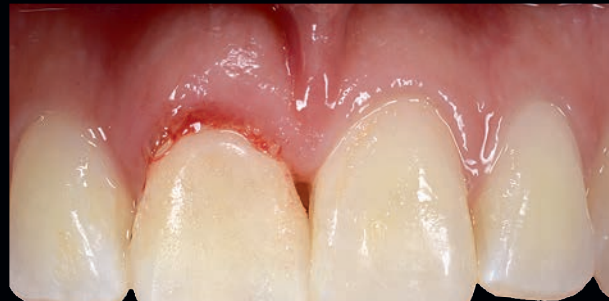16



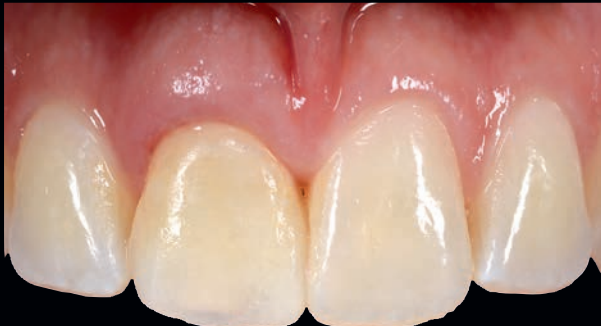17



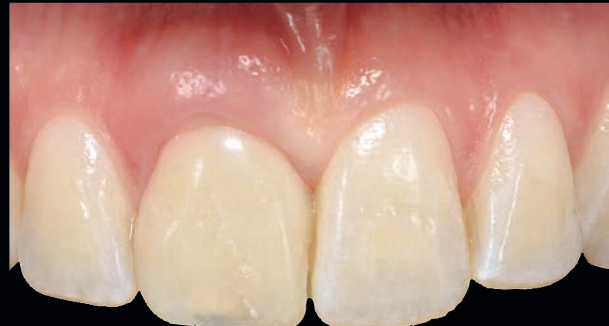18



19



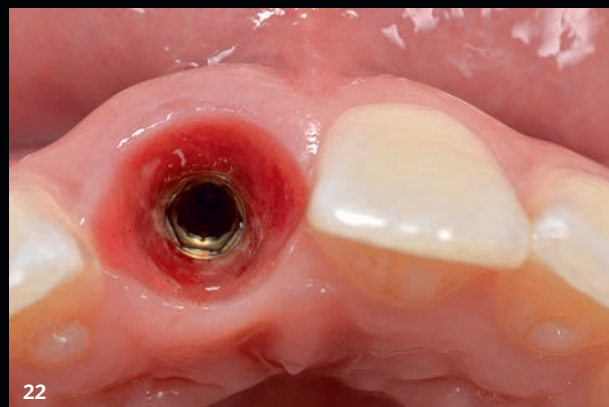20



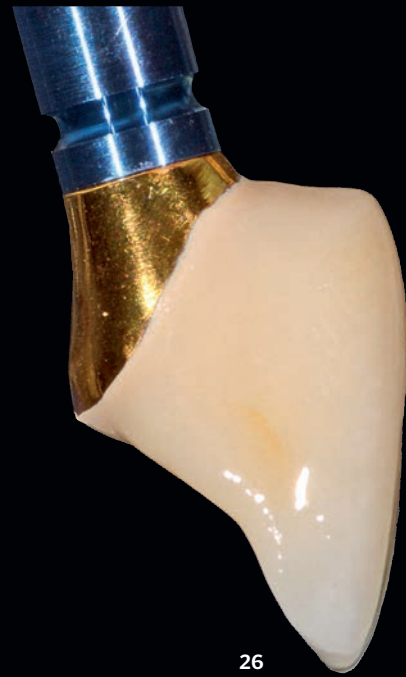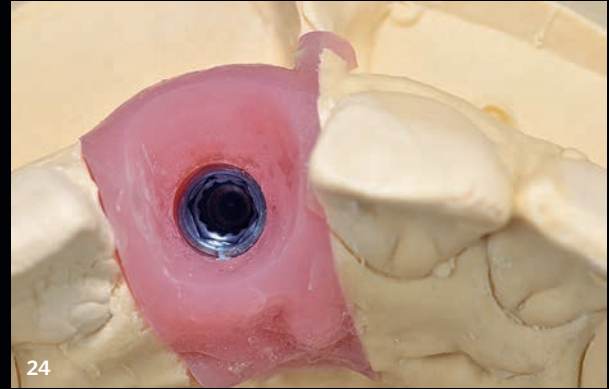
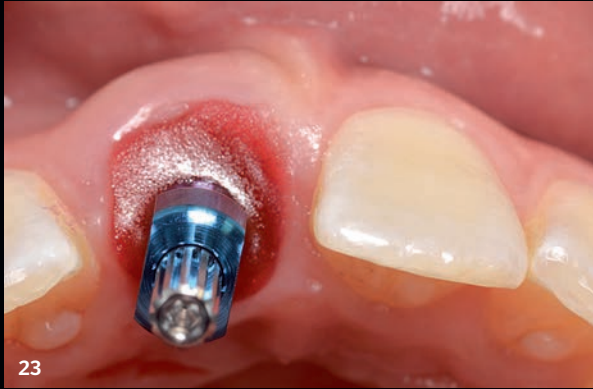21

returned to the office and showed resolution of the marginal gingival inflammation (Fig 20).

At this point, the patient embarked on an exchange student program in Europe and did not return for final impression making until 13 months postsurgery (Fig 21). The tissue was stippled and healthy, and it was clear that the disease had fully resolved upon first removal of the provisional restoration prior to impression making (Fig 22). Pattern Resin (GC America) was used to capture the soft tissue profile so

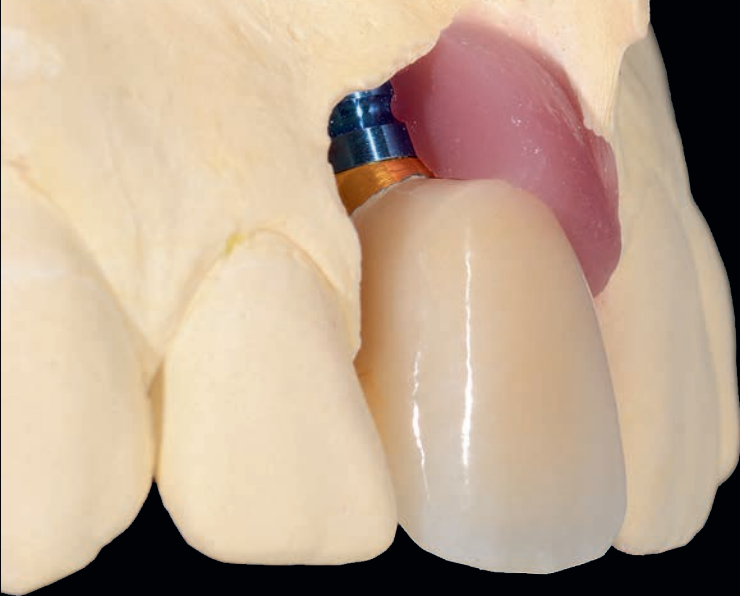

22

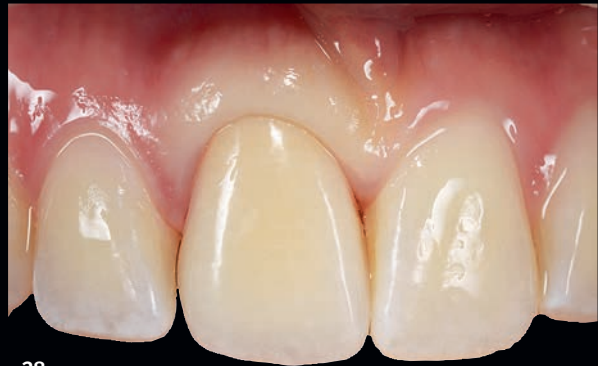

that an accurate cast could be created (Figs 23 and 24). A metal-ceramic screw-retained definitive restoration was made in the dental laboratory (Figs 25 and 26). Attention was paid to the midfacial subgingival contour of the restoration to support the soft tissues at the proper gingival level to match the contralateral central incisor (Fig 27). Soft tissue blanching can be seen upon final crown insertion (Fig 28).

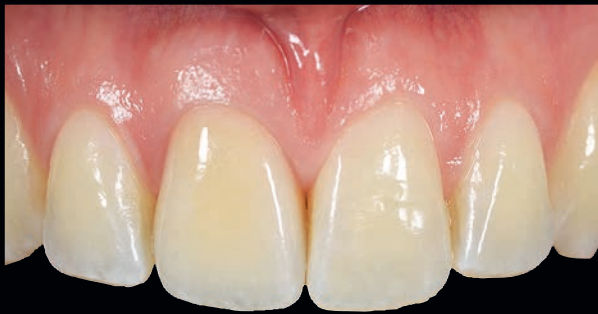The technique of nonsurgical tissue sculpting is an effective treatment strategy in soft tissue contouring. The implant restoration is well integrated and in harmony with the surrounding teeth, tissues, and esthetics at 3 years post-treatment (Figs 29 to 31). The postoperative periapical radiograph shows radiographic bone stability 3 years after treatment (Fig 32).



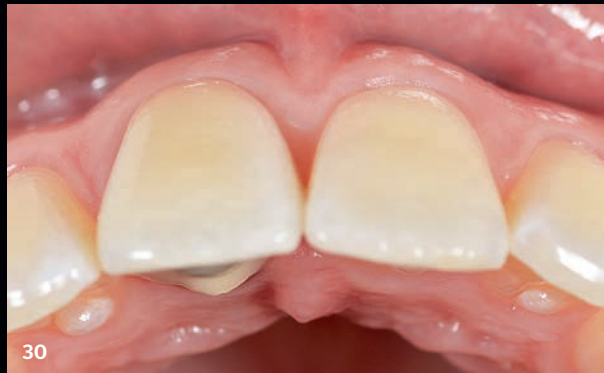27



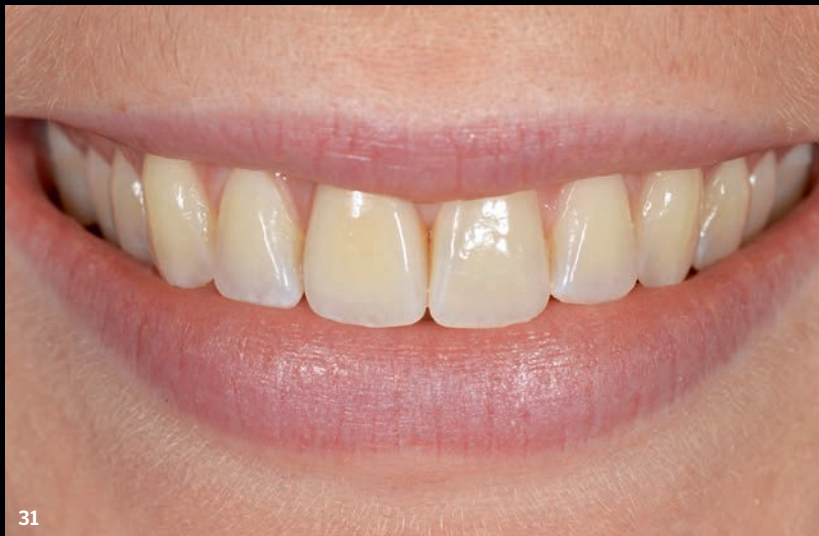28



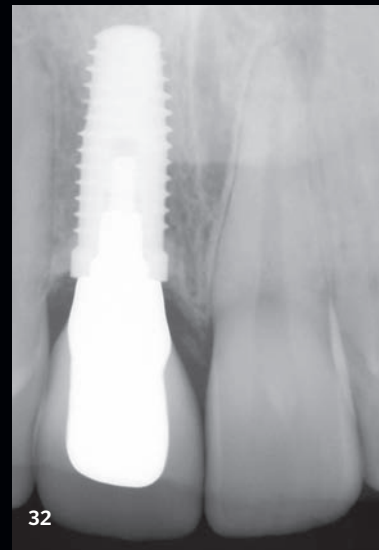
29



30



31



32

Challenges with Immediate Implant Placement

One of the biggest challenges that arises when most surgeons extract a tooth and place an implant into an extraction socket is what to do with the residual gap between the facial surface of the implant and the palatal aspect of the labial bone plate. Should a bone graft be placed? Is a bone graft necessary to achieve better survival rates of the implant in the esthetic zone? Will a bone graft improve osseointegration or bone-to-implant contact around the implant? Will a bone graft change the cell type that occupies the implant surface? Will a bone graft prevent ridge collapse, thereby enhancing esthetics and preventing tissue discoloration?

Several studies have reported high survival rates without bone grafting, which seems to support the conclusion that a bone graft is not critical for implant success.²⁻⁹ Probably the most common side effect of placing an implant into a fresh extraction socket is collapse of the facial ridge with midfacial recession. This occurs due to multiple factors: (1) the implant was placed or angulated excessively forward within the socket, leaving a paper-thin wall of bone, or (2) part of the buccal plate bone crest was missing during implant placement. Any of these clinical situations holds the potential risk for recession with immediate implant placement.^{19,20} Even though the implant will integrate, the case will be a failure cosmetically due to loss of the labial bone plate (Figs 33 to 35).

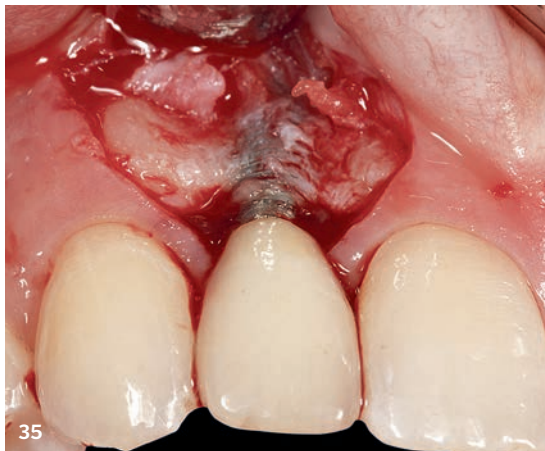
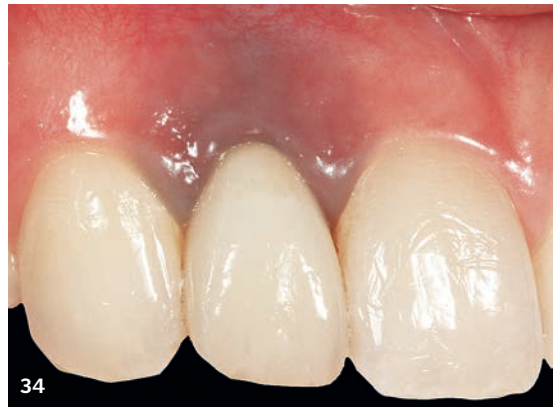
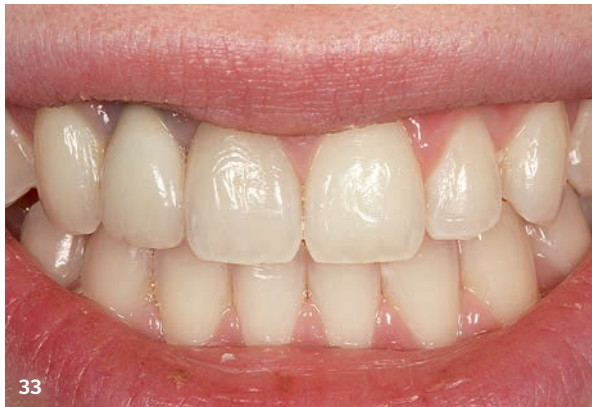
Fig 33 Dentofacial smile view of a patient who had received an immediate implant to replace the maxillary right lateral incisor at a previous dental office. Note the tissue discoloration associated with the implant and restoration. The dark color from the underlying titanium is distracting and unattractive.

Fig 34 Intraoral view of the maxillary lateral incisor clearly showing the extent and magnitude of the discolored implant restoration, which extends beyond the free gingival margin.

Fig 35 Following full-flap elevation to repair the site with a sub-epithelial connective tissue graft, note the lack of bone covering roughly half of the labial surface of the implant that leads to the dark discoloration of the tissues.

A second risk, and by no means less significant, is the potential loss of the interdental papilla following immediate (or delayed) implant placement (Fig 36). Several authors have suggested that a minimum distance of 1.5 mm be maintained between the implant and any adjacent tooth to maintain the crestal bone between the tooth and implant.^{21,22} The horizontal formation of biologic width and crestal pressure necrosis may be contributing factors in interdental crestal bone loss and recession if the implant-tooth distance is inadequate²³ (Fig 37). Even though Khayat et al showed no evidence of pressure necrosis (resorption) of crestal bone with extremely high insertion torque of up to 178 Ncm, they did not measure the bone thickness surrounding the implants postinsertion.²⁴ Subsequently, Barone et al correlated crestal bone loss with osseous thickness, concluding that there is a greater risk of hard tissue loss with high insertion torque (pressure) when the contiguous bone dimension is less than 1.0 mm.²⁵

The clinical reality is that implants “drift” and migrate within the extraction socket to the side of least resistance both labially and interdentally (ie, the gap) during final placement to achieve the highest insertion torque value for primary stability. With the tapered coronal portion, the implant head is frequently placed subcrestally and in contact with the palatal bone during insertion. As the implant is torqued into place, the implant “bounces” off the palatal bone wall and migrates to the facial aspect of the socket (Fig 38). The use of a dynamic or static guide may be helpful to keep the osteotomy clean and the implant position on target for the intended placement.

It is important to understand that not all extraction sockets are the same, and not all are suitable for immediate tooth replacement therapy. See chapter 2 for more information on the bone gap as well as chapters 3 and 4 on type 2 and type 3 sockets, respectively.

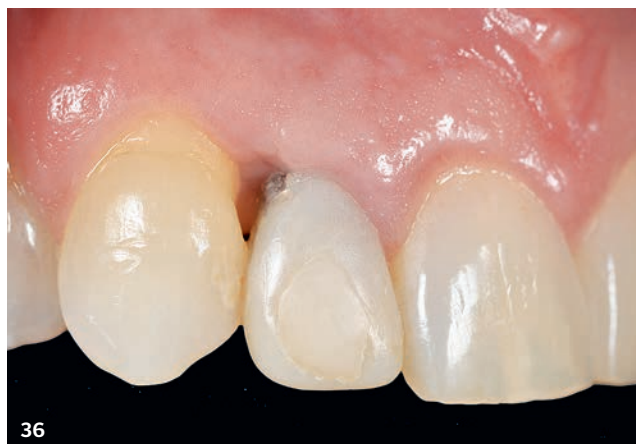

Fig 36 Intraoral view of an implant placed excessively facial and distal in close proximity to the adjacent canine tooth. Note the loss in height of the mesio-facial papilla of the canine, while the mesiopalatal aspect of the papilla is still present. It can be this subtle if placement is not ideal in the esthetic zone.

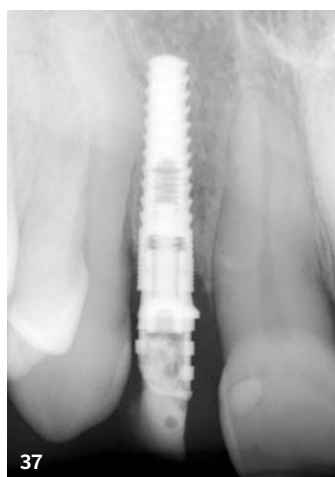

Fig 37 Periapical radiograph of the lateral incisor shown in Fig 36 revealing the close tooth-implant proximity to the mesial aspect of the canine and the accompanying crestal bone loss.

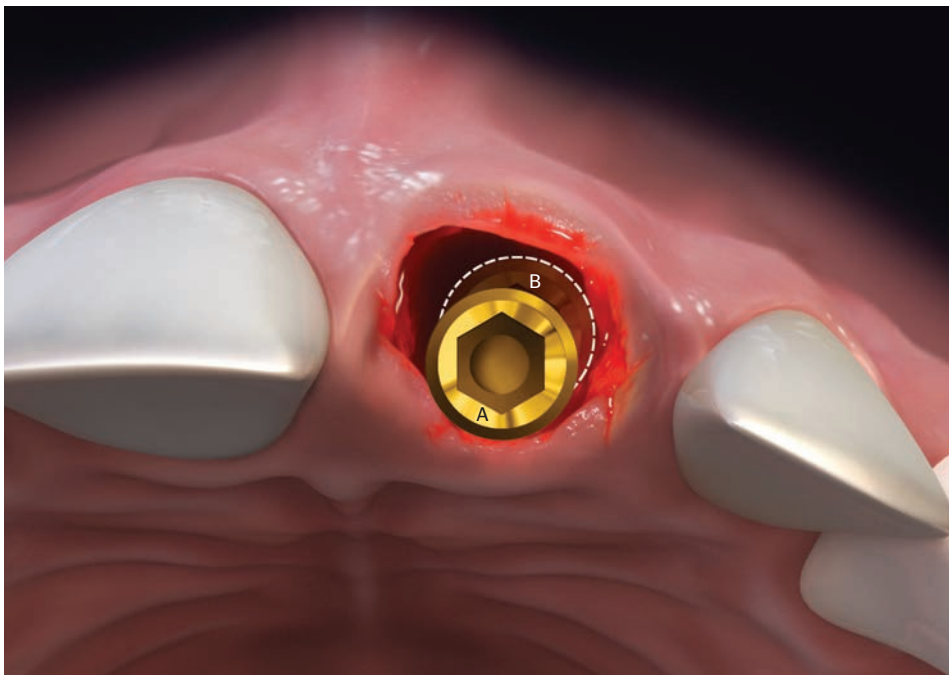


Fig 38 Illustration of the preferred palatal position of an implant within an extraction socket (A), toward the cingulum of the tooth, for screw retention of the restoration. However, the implant can bounce off the palatal wall and migrate not only labially but also slightly distally (B). The use of a static guide may be helpful to keep the implant on track and in the correct final position.

Classification of Extraction Sockets

There are three different types of sockets (Figs 39 to 41) following tooth removal, and all have the prospective risk of midfacial recession.²⁶ Type 1 sockets are the most ideal clinical situation because all the bone and soft tissues are present (see Fig 39). Type 2 sockets are less ideal because they present with a dentoalveolar dehiscence defect of the labial plate of bone that increases the risk of midfacial recession (see Fig 40 and chapter 3). Type 3 sockets present with an existing midfacial recession deficiency indicative of loss of both hard and

soft tissues (see Fig 41 and chapter 4). Type 1 sockets are more predictable to treat than the other classification types; however, there are specific treatment protocols and indications that allow these other types to be treated under the right conditions. Type 2 sockets are clinically deceiving because the soft tissue is available and appears the same as Type 1 sockets prior to tooth removal, but this soft tissue is only supported by the tooth root and not the underlying bone, which is absent. If the buccal plate is partially missing, there is risk of gingival recession when the tooth is extracted and an implant is placed. This is where most clinicians can get into trouble.